

**Case 41 Münster 4:
male, 57 years (V-T)**

**CTO crossing with new OCT-image
guided and steerable catheter**

Operators: A. Schwindt, E. Beropoulos

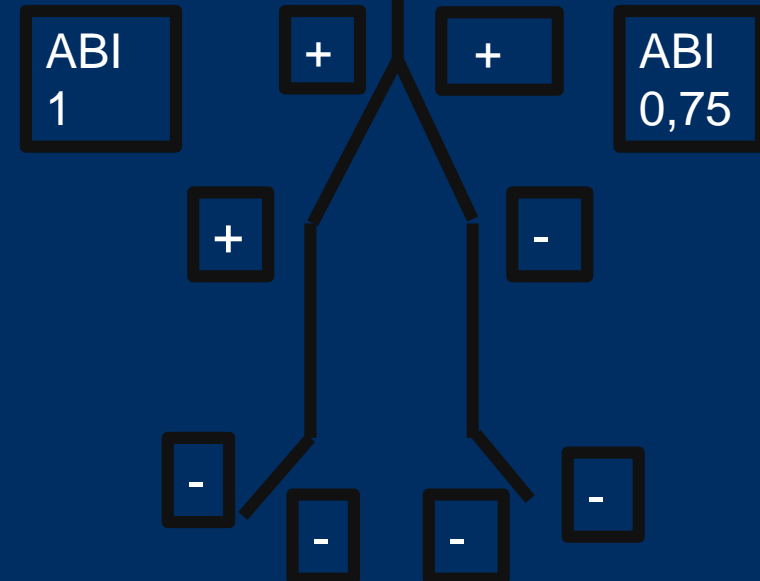
Case 41 Münster 4: male, 57 years (V-T)

- **Clinical data:**

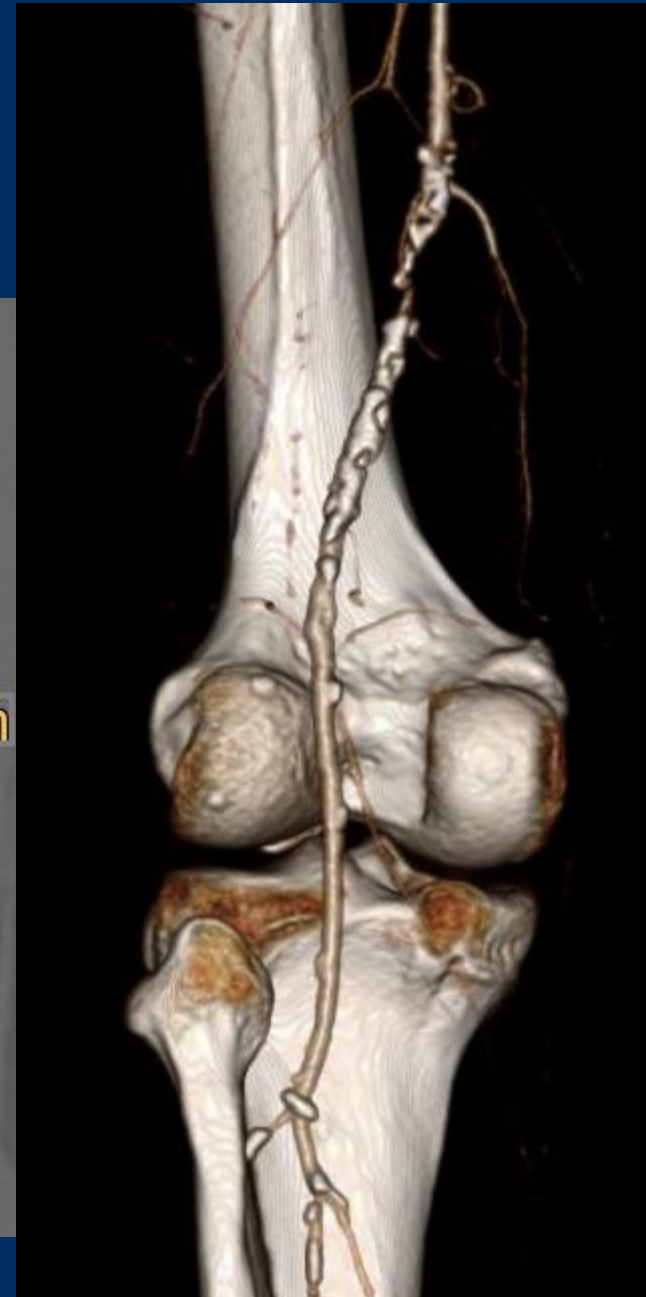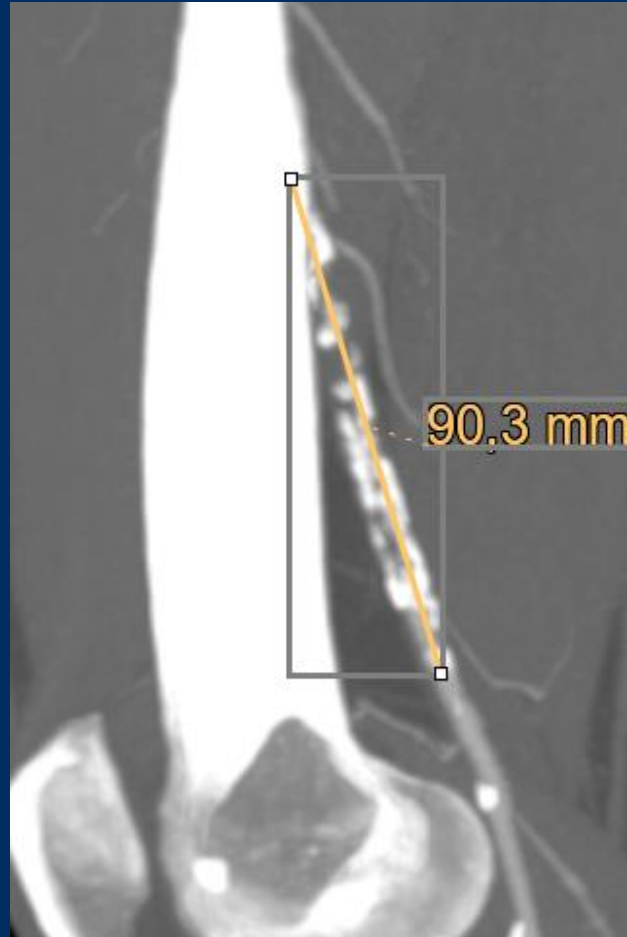
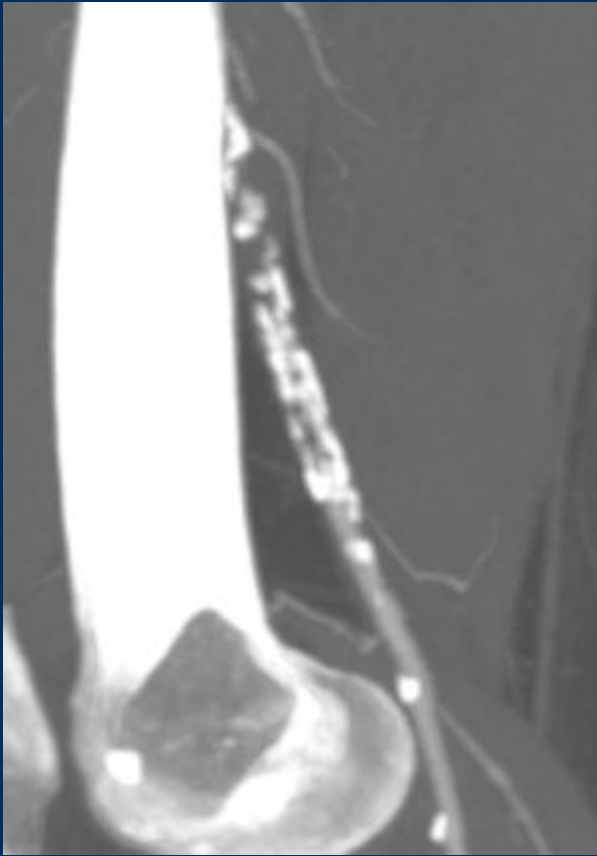
- PAD Rutherford III left leg with WD limited to 200 meters
- Symptoms since 2 yrs

- **Risk factors:**

- arterial hypertension
- COPD
- DM



Case 41 Münster 4: male, 57 years (V-T)



Case 41 Münster 4: male, 57 years (V-T)

- Procedural steps:
 - antegrade US guided access right CFA
 - introduction of a 6F 10cm Sheath (Terumo)
 - recanalization of distal SFA/prox. Pop. artery CTO guided with 6F 140cm TigerEye (Avinger)
 - Directional OCT guided atherectomy with 7F Pantheris (Avinger)
 - Postdilation with Passeo lux DCB

