

**Case 39 Hamburg 2:
male, 78 years (W-N)**

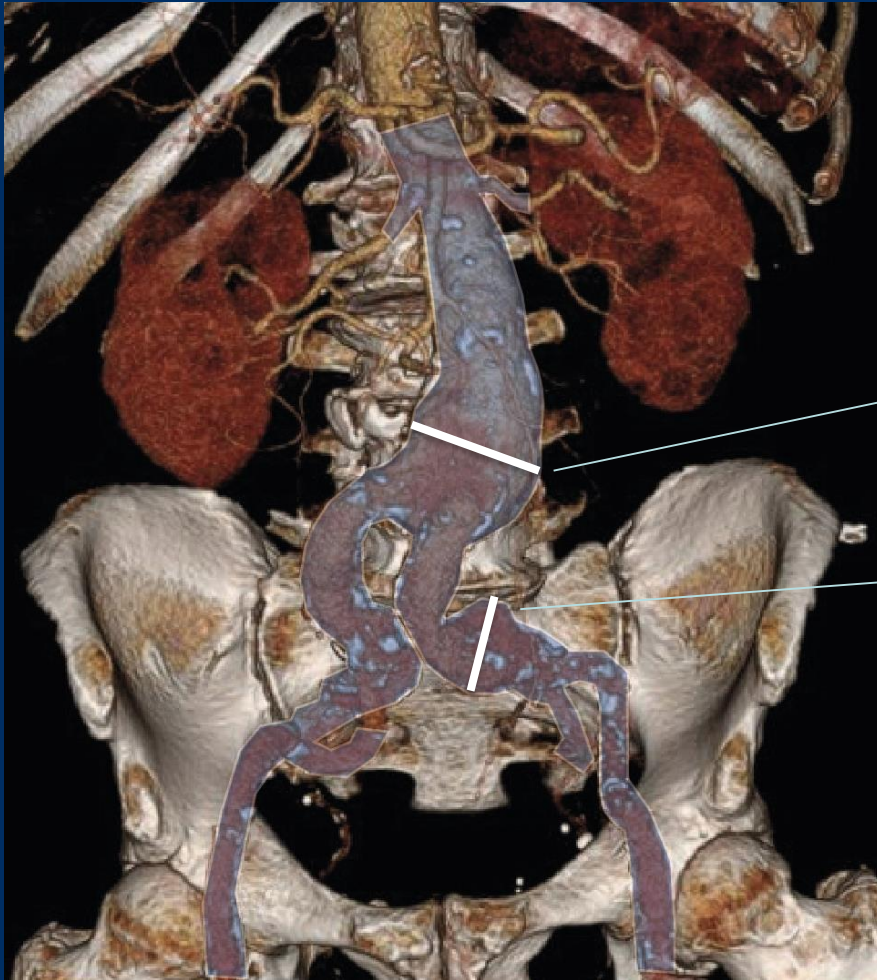
**Iliac sidebranch EVAR in aortoiliac
aneurysm with severe iliac
tortuosity**

Operators: T. Kölbel, C. Behrendt

Case 39 Hamburg 2: male, 78 years (W-N)

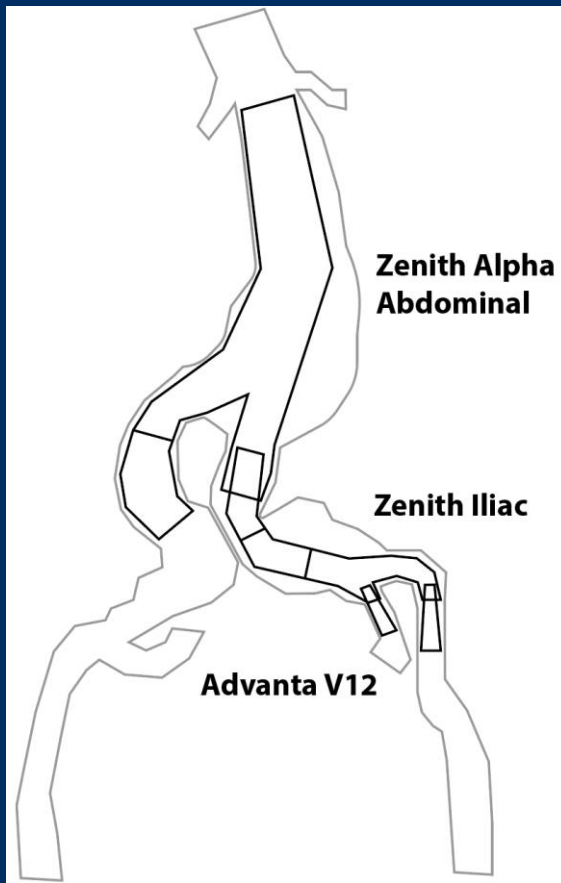
- **Clinical data:**
 - Aortoiliac aneurysm 56 mm
- **Risk factors / Present state:**
 - Severe multisite artery disease:
coronary artery disease,
bilateral carotid artery stenosis (50-80%)
 - History of coronary bypass (2002) and
percutaneous coronary intervention (2017)
 - Arterial hypertension
 - Dyslipidaemia

Case 39 Hamburg 2: male, 78 years (W-N)



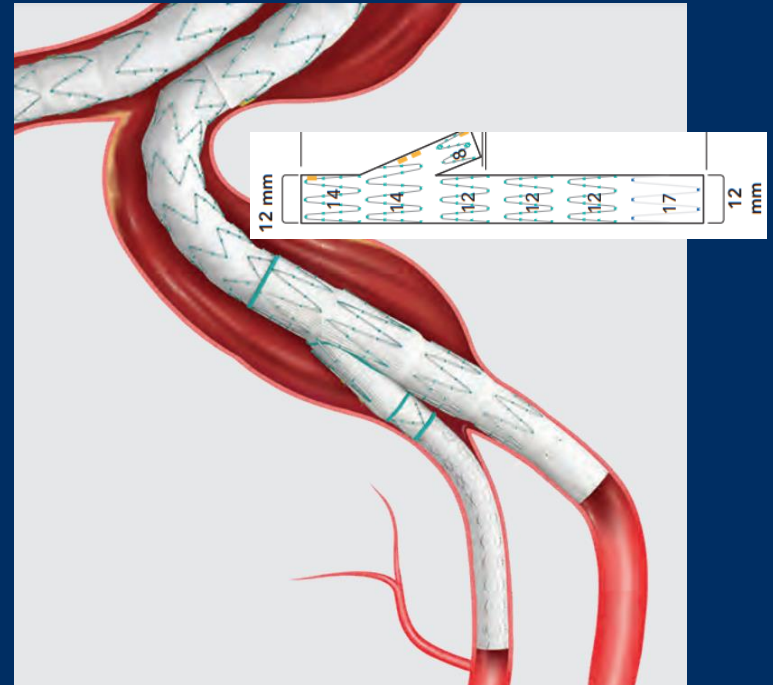
- **Aortobiiliacal aortic aneurysm**
 - Infrarenal: 56mm, asymptomatic
 - Left iliac: 36mm, asymptomatic
 - Severe iliac tortuosity

Case 39 Hamburg 2: male, 78 years (W-N)



12F

22F



Case 39 Hamburg 2: male, 78 years (W-N)

- **Procedural steps:**
 - **1. Right common femoral artery access (12F), left common femoral artery access (22F)**
 - **2. Carbondioxide and saline flushing of ZBIS, Zenith Alpha Abdominal and Zenith Iliac Spiral Limbs**
 - **3. ZBIS introduction left CFA, snaring and crossover maneuver**
 - **4. Angiography and partial ZBIS-deployment**
 - **5. Internal iliac artery catheterization through crossover 12F Flexor sheath, Full ZBIS deployment**

Case 39 Hamburg 2: male, 78 years (W-N)

- **Procedural steps:**
 - 6. Bridging stent deployment (Advanta V12, Getinge) and kissing balloons
 - 7. Zenith Alpha Abdominal introduction and deployment
 - 8. Extension to right common iliac artery
 - 9. Bridging component to left sided ZBIS
 - 10. Self-expanding stent left external iliac artery and final angiography