

**Case 37 Abano Terme 2:
male, 67 years**

Right BTK Recanalization

**Operators: M.Manzi, C.Brigato,
E.Sultato**

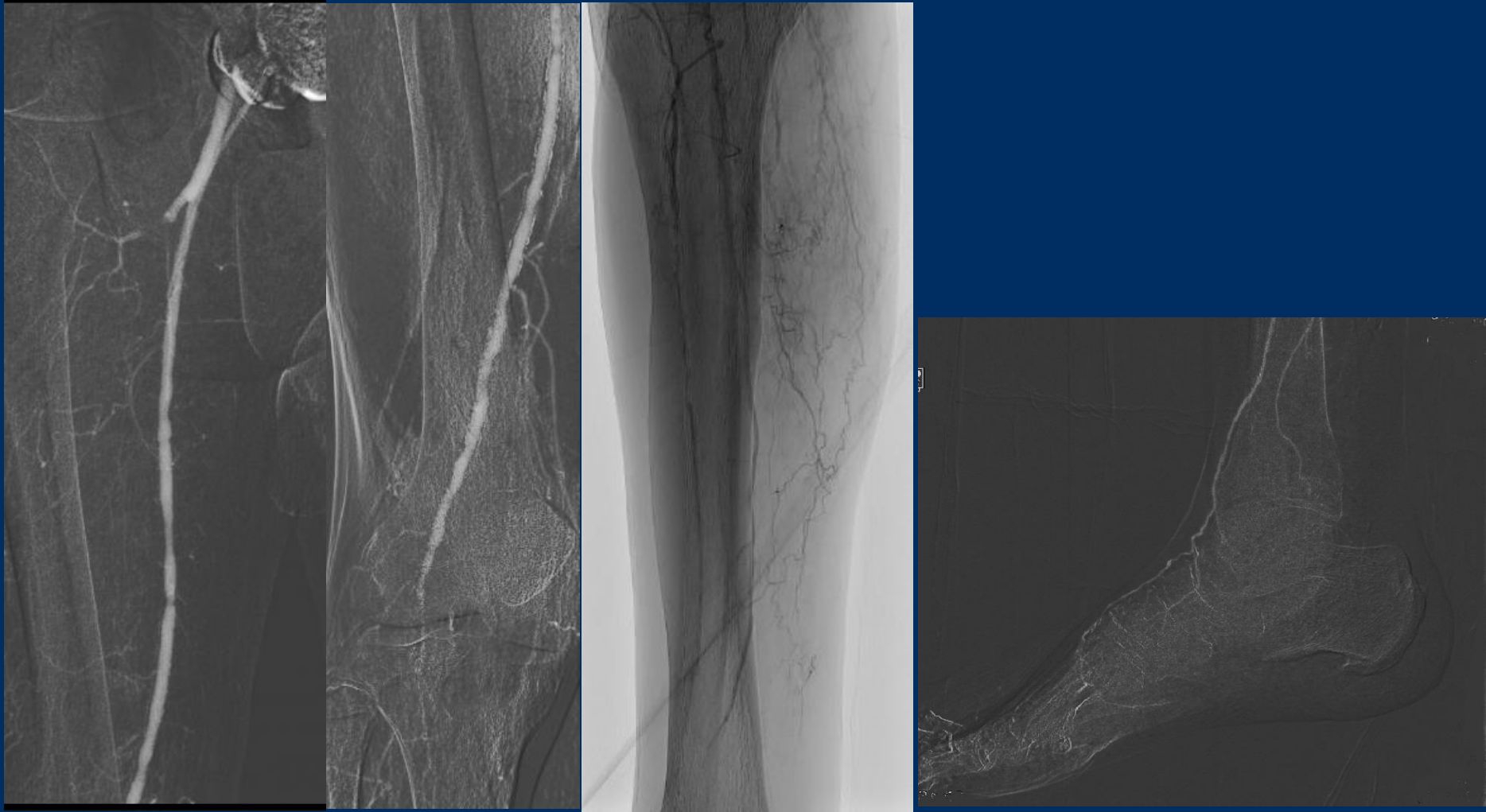
Case 37 Abano Terme 2: male, 67 years

- **Clinical data:**
 - PAOD Rutherford 6, gangrene in previous 1° Toe amputation;
 - No Pulses

Case 37 Abano Terme 2: male, 67 years

- **Risk factors:**
 - Hypertension;
 - Diabetes type 2;
 - Ischemic Heart Disease;

Case 37 Abano Terme 2: male, 67 years CO2 angio 4/2020



Case 37 Abano Terme 2: male, 67 years

- **Procedural Steps:**

- Right groin antegrade 6F US Guided;
- CO2 angio study and IVUS;
- Retrograde access in case of failure to pass the lesion;
- 0,014 and High Pressure non compliant Jade PTA;
- -Lutonix DEB ;