

**Case 33 Singapore 1:
female, 71 years (W-A-C)**

SFA stenosis

ATA near occlusion

TPT and peroneal disease

Operators: E. Choke, T. J. Sheng, Ch.S. Chuen

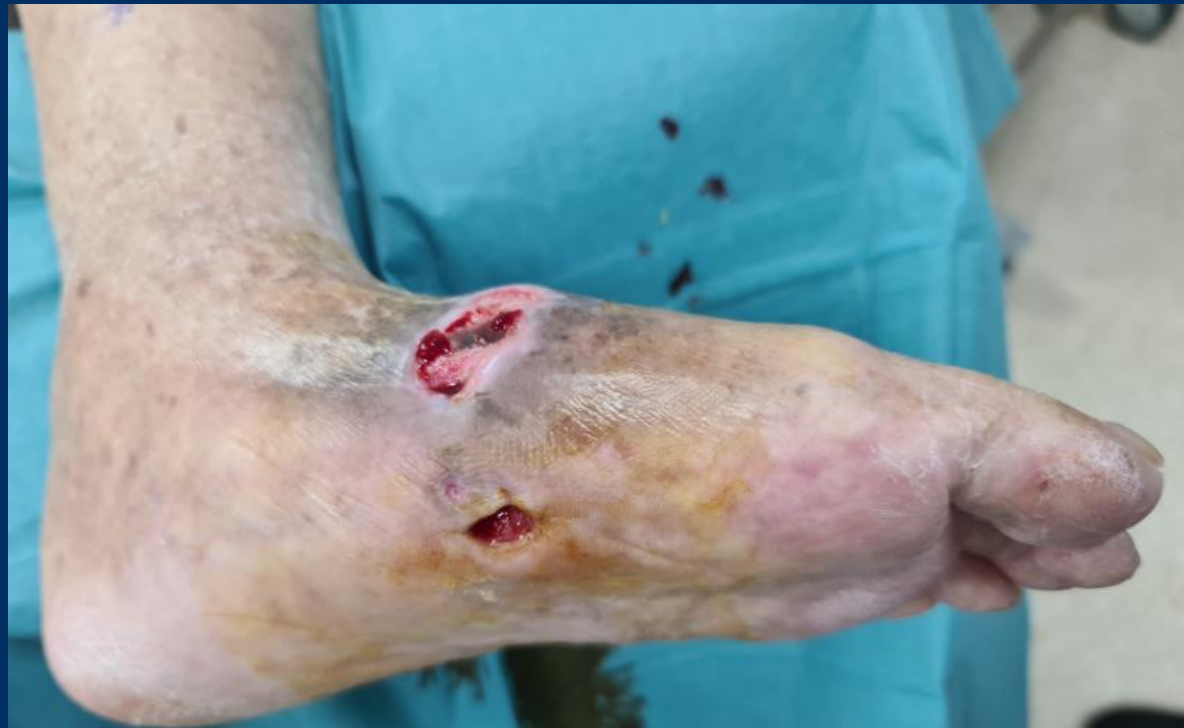Case 33 Singapore 1: female, 71 years (W-A-C)

- **Clinical data:**
 - PAOD Rutherford stage 5
 - Non healing wound left charcot foot
- **Risk factors:**
 - Poorly controlled diabetes mellitus
 - Ischemic heart disease, STEMI 2011, EF 45% 2015
 - HTN and HLD

Case 33 Singapore 1: female, 71 years (W-A-C)

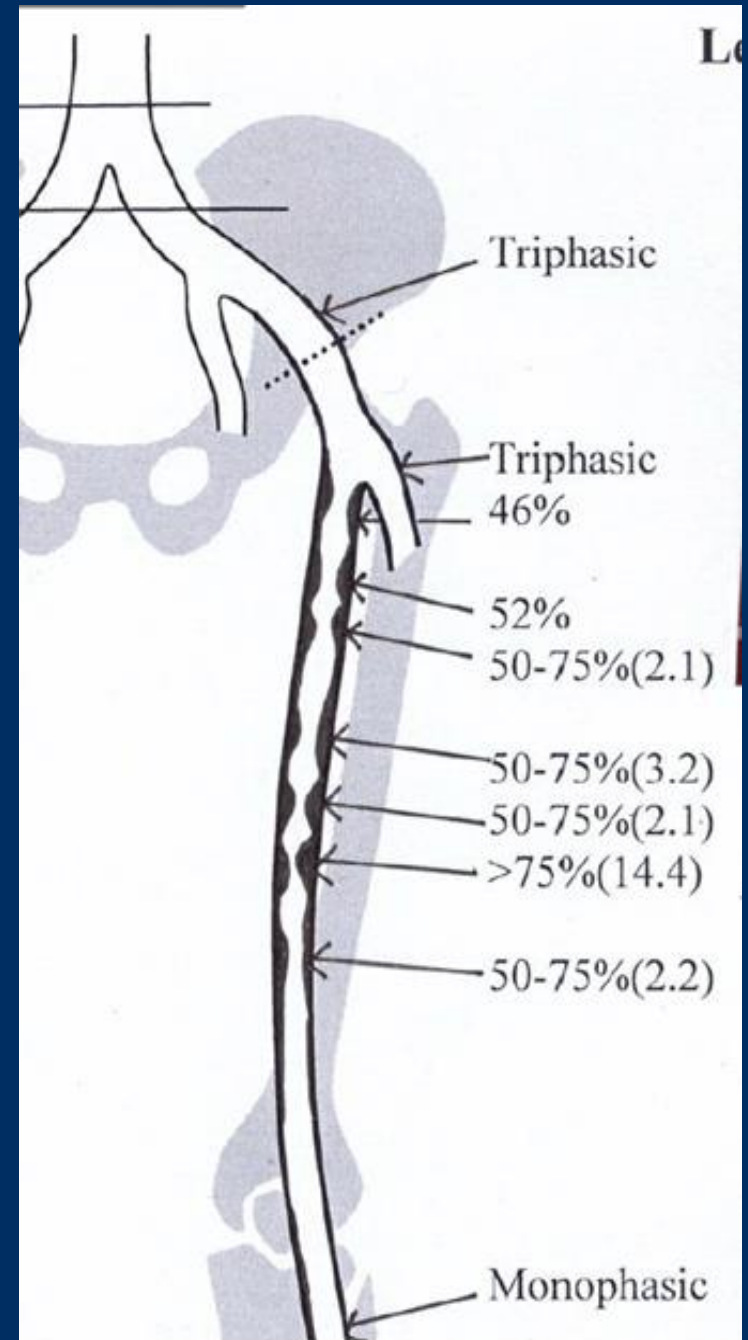
- **Present State:**

- Charcot foot
- Left foot wound debridements Dec 2020 and Jan 2021
- Deteriorating wound (getting bigger)
- No previous angioplasty



Case 33 Singapore 1: female, 71 years (W-A-C)

- DUS
 - SFA
 - Diffuse stenosis
 - High grade stenosis distal SFA



Case 33 Singapore 1: female, 71 years (W-A-C)

- DUS

- ATA

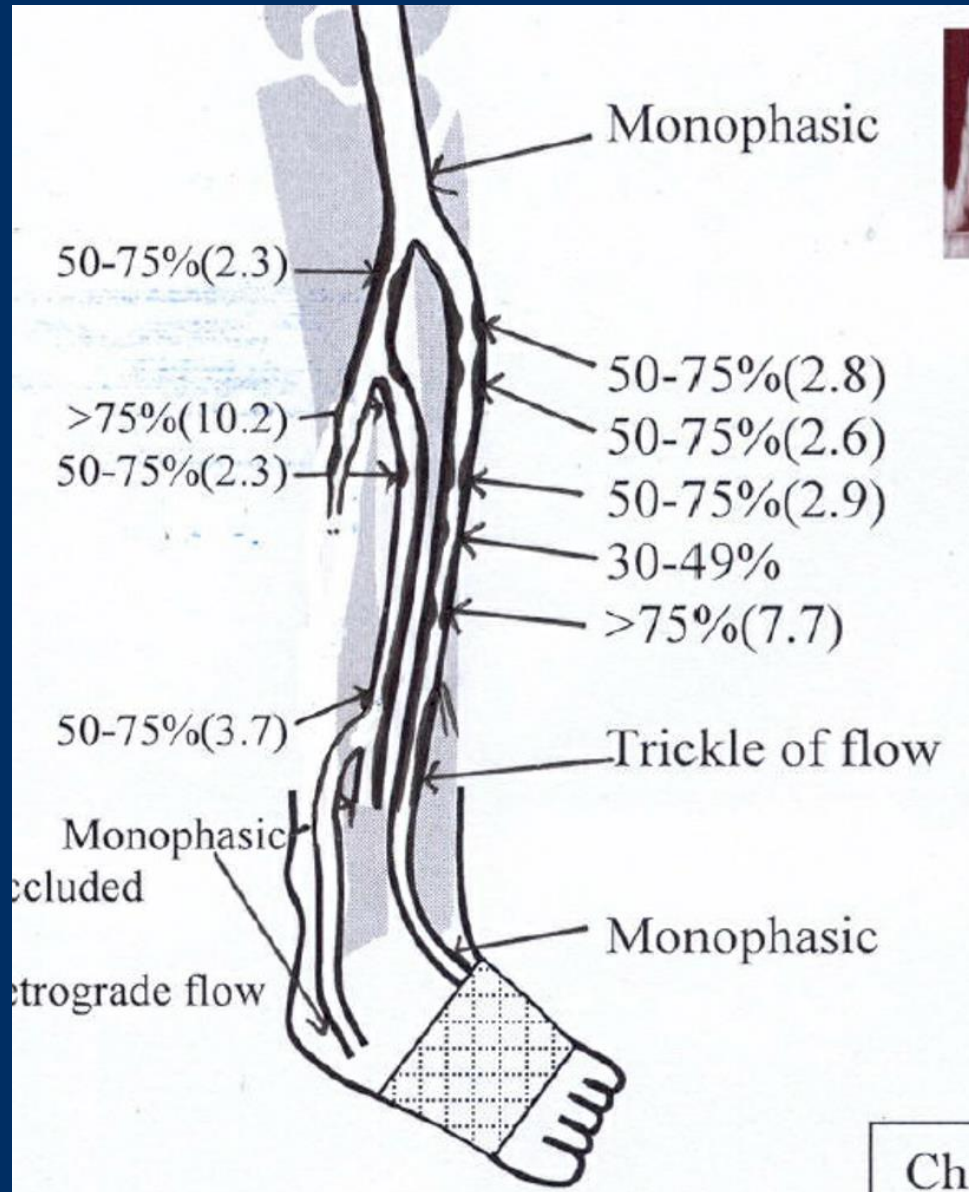
- Diffuse stenosis
- near occlusion dATA

- Peroneal

- Proximal high grade stenosis

- Toe pressures

- 51mmHg left leg
- 95mmHg right leg



Case 33 Singapore 1: female, 71 years (W-A-C)

- **Procedural steps:**

- Placement of a 5F brite tip sheath (Cordis)
- Passage of SFA with 0.018 V-18™ Control Wire™ (Boston Scientific) and 4Fr Berenstein catheter
- Passage of ATA/Peroneal with 0.018 V-18™ Control Wire™ (Boston Scientific) and 2.6Fr CXI Support Catheter (Cook)
- Alternative 0.014 Hi-Torque Command™ ES wire (Abbott)
- Retrograde access via DP puncture under USS guidance if necessary

Case 33 Singapore 1: female, 71 years (W-A-C)

- **Procedural steps:**

- SFA

- POBA with 5mm Mustang balloon catheter OTW 0.035 (Boston Scientific)
 - SCB with 5mm MagicTouch PTA sirolimus coated balloon (Concept Medical)
 - Stenting with Lifestent (BD) if necessary

- ATA and Peroneal

- POBA with non-compliant 3mm Achilles balloon catheter OTW 0.018 (Angeion Medical)
 - SCB with 3mm MagicTouch PTA sirolimus coated balloon (Concept Medical)
 - Stenting with Abluminus sirolimus coated stent (Concept Medical) if necessary