

**Case 31 Leipzig 12:
male, 59 years**

**Pre-EVAR Coilembolisation of
Aortic Sidebranches**

Operators: A. Schmidt, D. Branzan

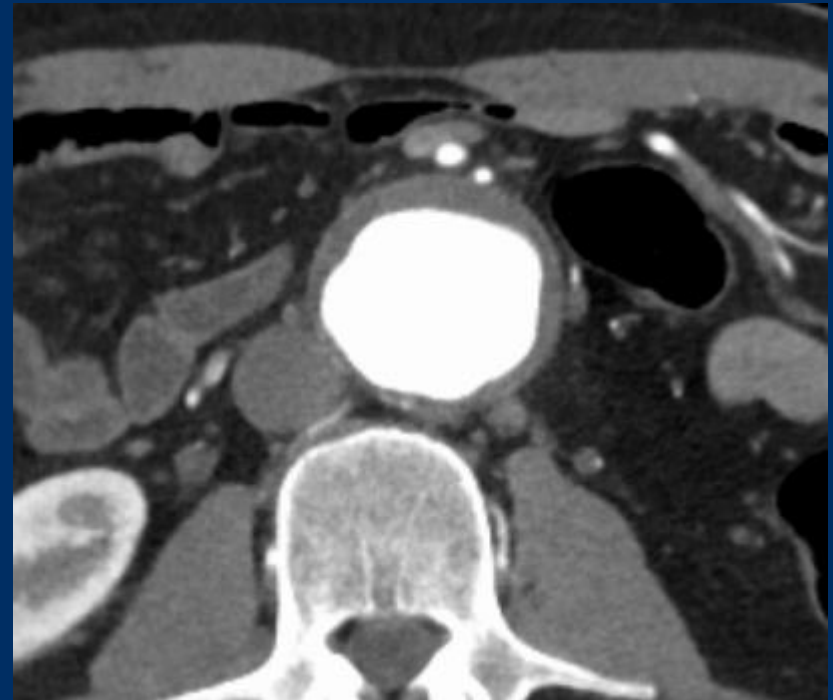
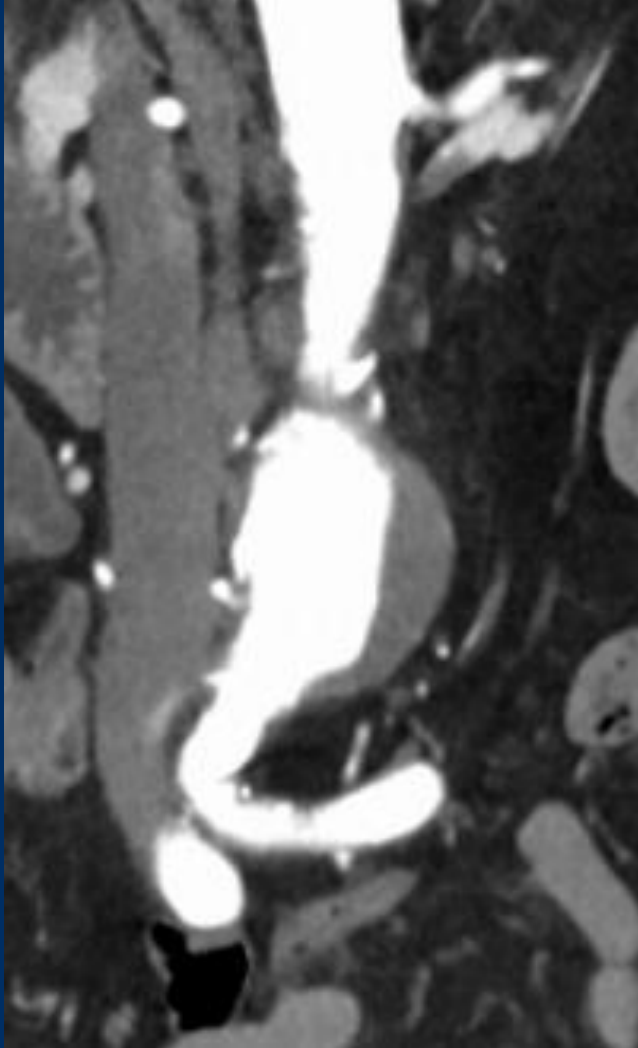
Case 31 Leipzig 12: male, 59 years

- **Clinical data:**
 - Incident finding of an infrarenal aortic aneurysm
 - Esophageal carcinoma, Chemotherapy end of 2020
 - Surgery planned

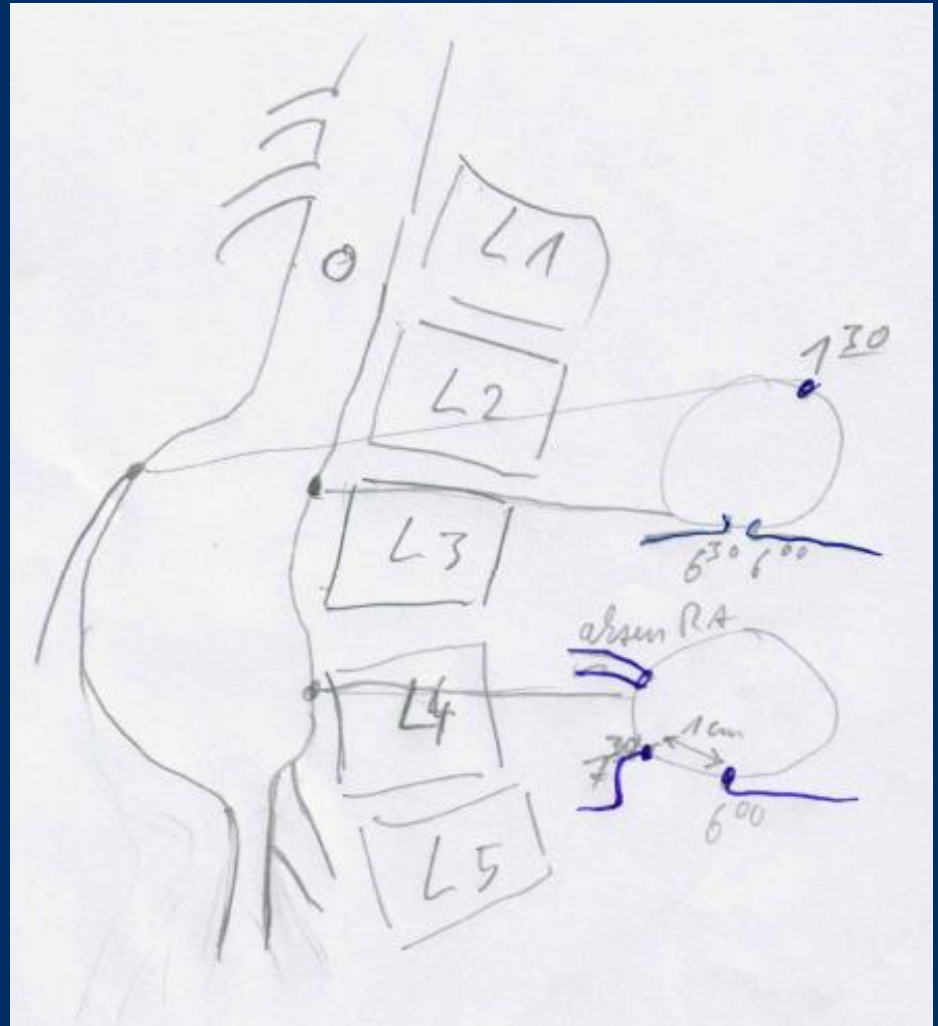
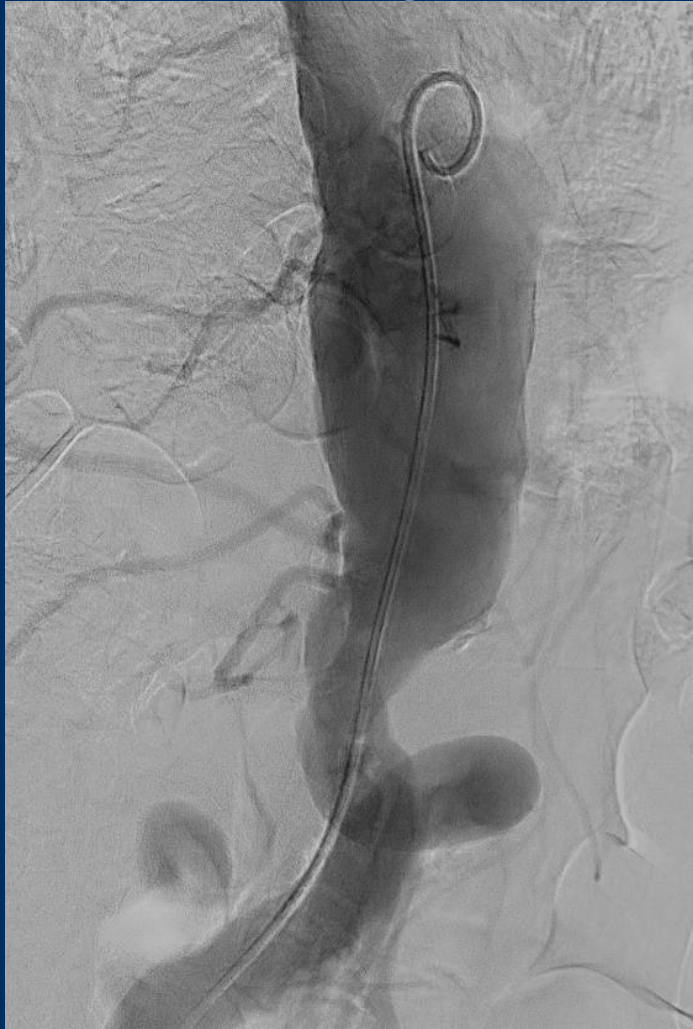Case 31 Leipzig 12: male, 59 years

- **Risk factors:**
 - Hypertension
 - HLP
 - Adipositas
 - Smoker

Case 31 Leipzig 12: male, 59 years



Case 31 Leipzig 12: male, 59 years




10ml KM RAO 50°

Case 31 Leipzig 12: male, 59 years


- **Procedural Steps:**
 - Right femoral access 6Fr.
 - IMA-6Fr. MACH I Guiding-catheter (BSCI)
 - 5Fr.-0.038" In SOS Omni Selective 3 catheter (Angiodynamics)
 - 5Fr.0.038" SIM-catheter
 - Lantern Microcatheter (Penumbra)
 - Ruby Coils (Penumbra)

Penumbra Coils

„Standard“-Coils

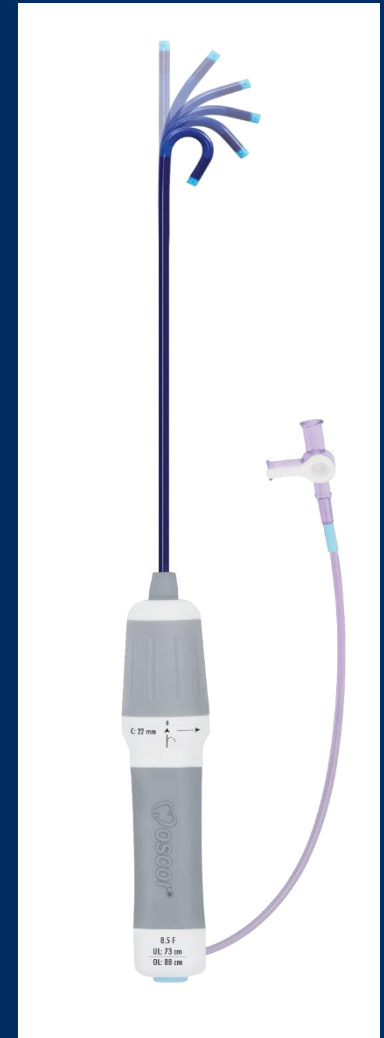

3-D / Volume-Coils



e.g. Penumbra Ruby Coil

- Large primary diameter: 0.020"
- Similar to .35" system coils
- But fit through microcatheter



Deflectable Steering
Guiding Sheath
(Oscor)