

**Case 29 Münster 3:
female, 57 years (G-B)**

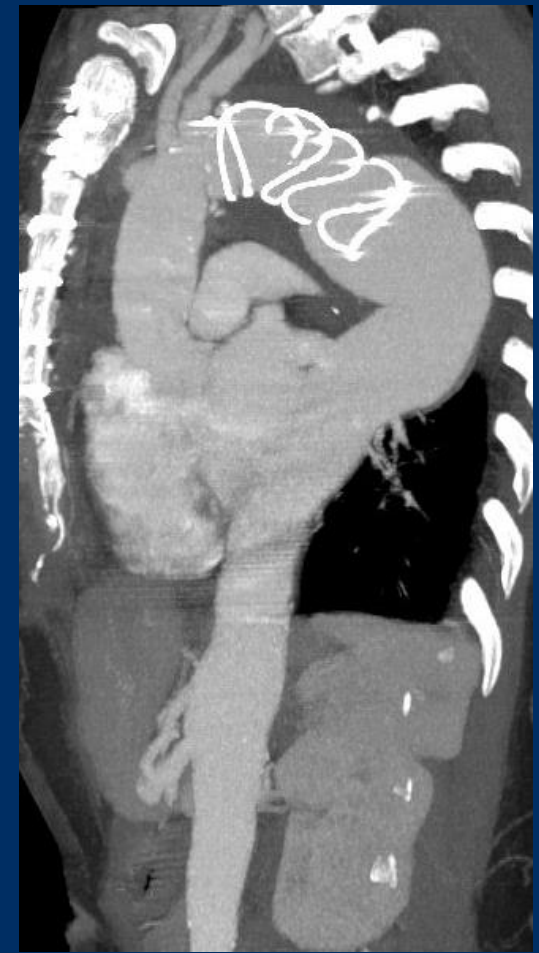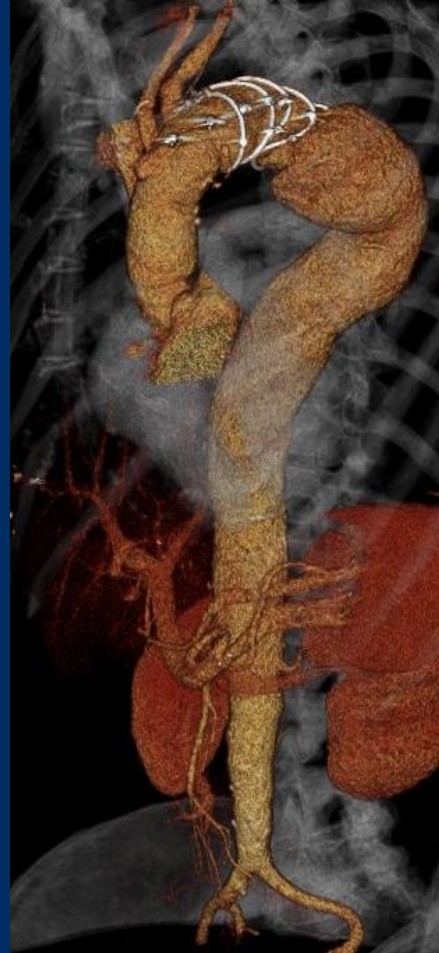
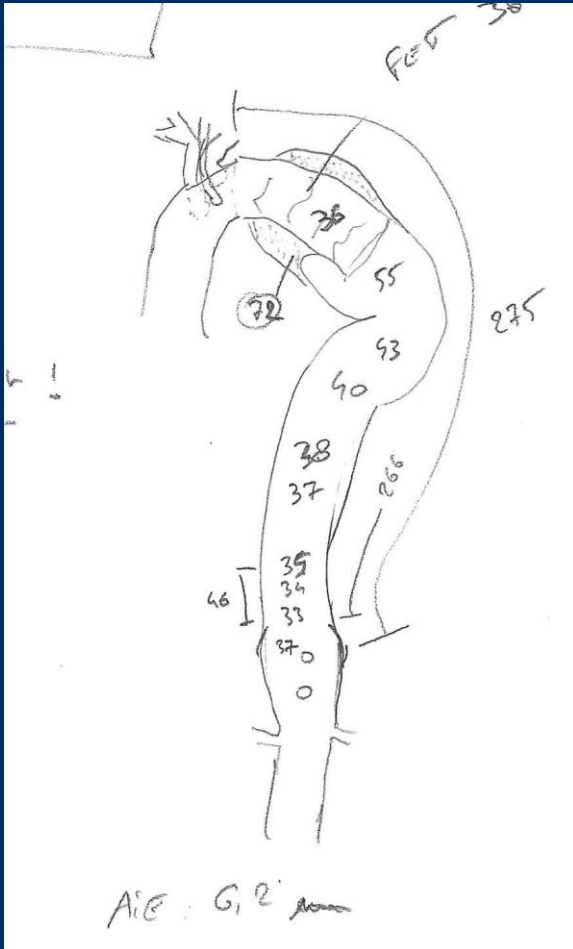
**Cook thoracic solution – expand your
treatment options**

Operators: M. Austermann, M. Bosiers

Case 29 Münster 3: female, 57 years (G-B)

- **Clinical data:**
 - 72mm large thoracic Aneurysm with previous hybrid aortic arch replacement: open total aortic arch replacement with frozen elephant trunk (12/2020)
- **Risk factors:**
 - Narrow access vessels

Case 29 Münster 3: female, 57 years (G-B)



Case 29 Münster 3: female, 57 years (G-B)

- **Procedural steps:**
 - 1. Percutaneous acces transfemoral and transbrachial
 - 2. Creating a pull-through-wire (4m Terumo wire; Indy Vascular Retriever, COOK)
 - 3. TEVAR: Zenith alpha (COOK)
 - 4. Closure of the groin with ProstarXL (Abbott) and Angioseal (Terumo)