

**Case 22 Leipzig 10:  
male, 81 years**

**Recorded case:**

**Heavily calcified SFA occlusion left**

**Operators: A. Schmidt, A. Fischer**

# Case 22 Leipzig 10: male, 81 years

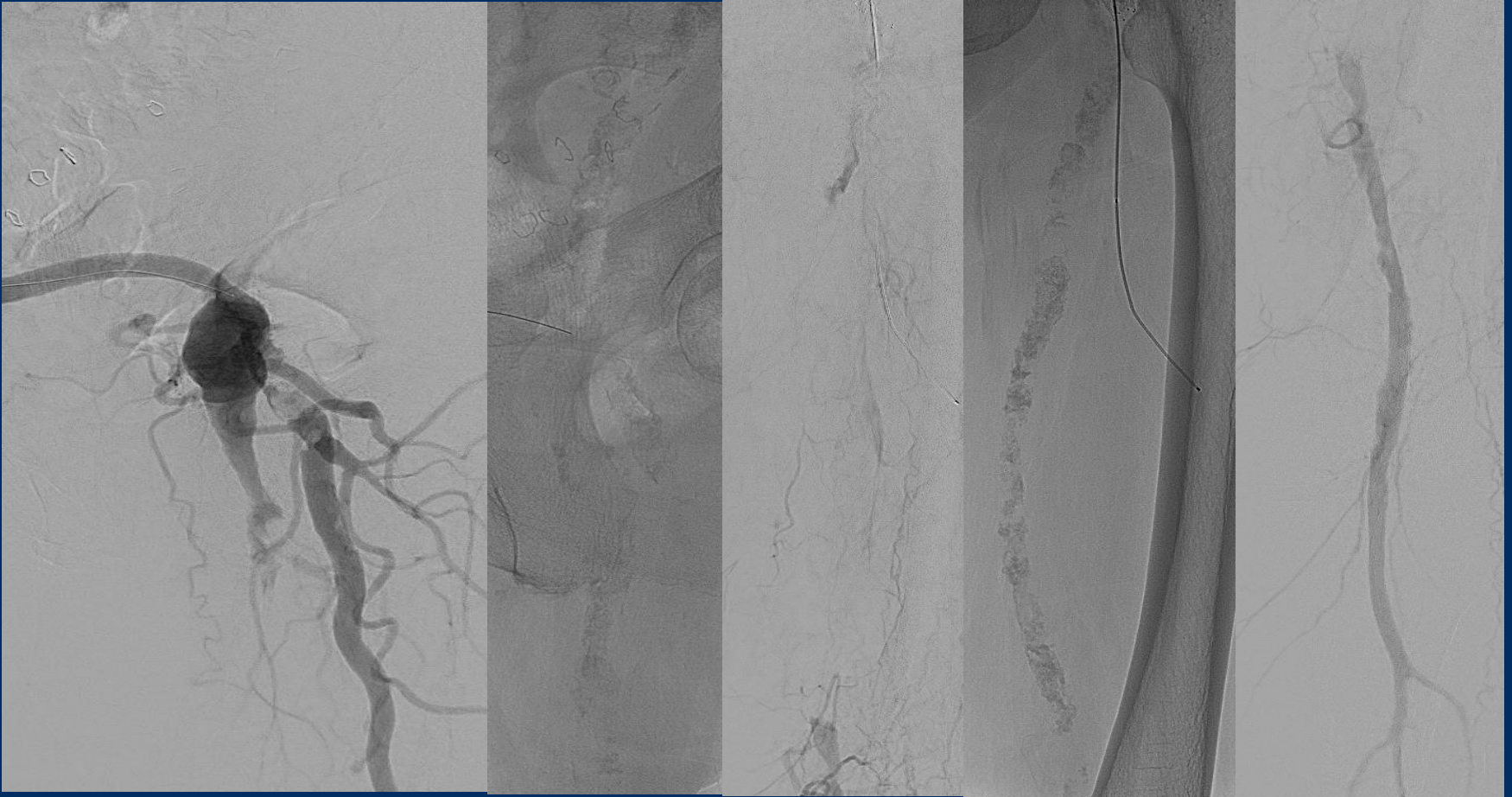
- **Clinical data:**

- PAOD Rutherford 3, claudication left calf, walking capacity 100m
- ABI right 0.67
- Hybrid revascularization 10/2018 (TEA right groin, PTA/Stent SFA)
- Femorofemoral crossover bypass right to left

# Case 22 Leipzig 10: male, 81 years

- **Risk factors:**
  - Coronary heart disease
  - Hypertension
  - Renal impairment
  - HLP

# Case 22 Leipzig 10: male, 81 years



# Case 22 Leipzig 10: male, 81 years

- **Procedural Steps:**
  - Antegrade approach bypass
  - Guidewire passage (retrograde puncture in case of failure)
  - Tumescence anesthesia (Bullfrog device)
  - “Crack and Pave”