

**Friday 29th January 2021, 17:15 – 17:35**

**Recorded Case:**

**Recurrent stenosis left common  
carotid artery**

**Operators**

**Andrej Schmidt, Matthias Ulrich and  
Holger Staab**

# Recorded Case: Recurrent stenosis left common carotid artery

## Clinical data

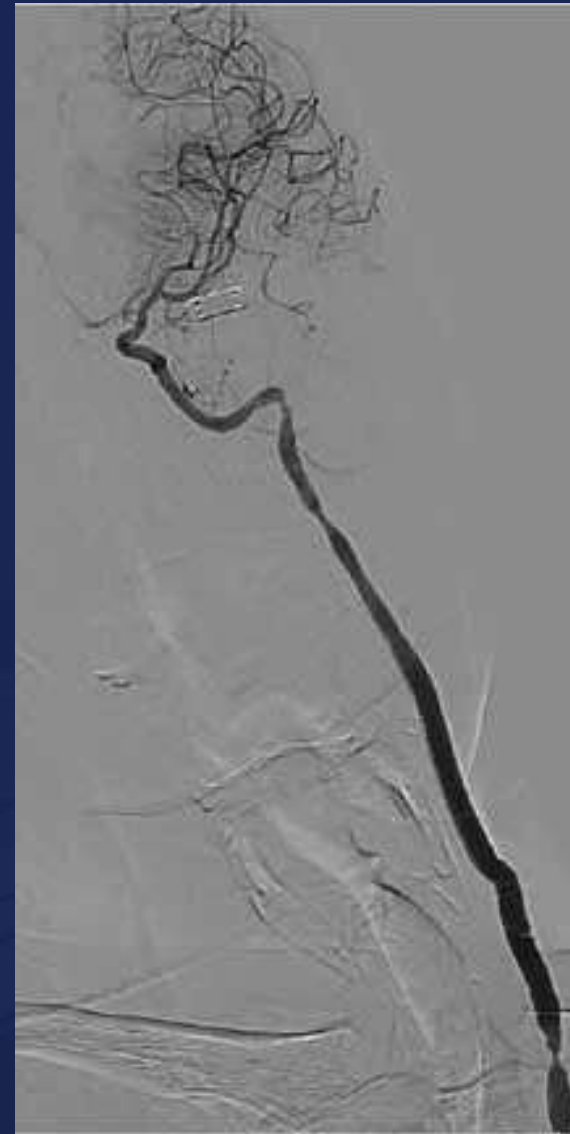
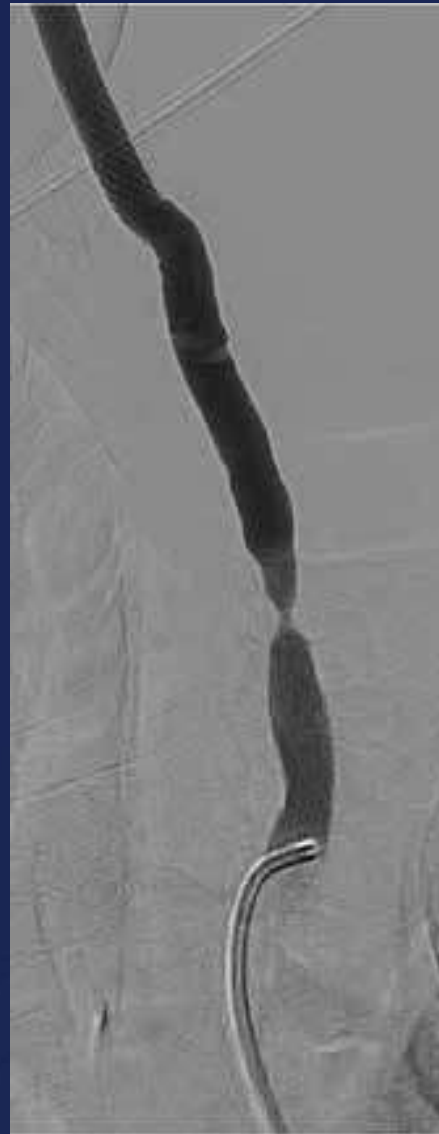- 56y male patient
- Recurrent stenosis left common carotid artery at the proximal anastomosis of a prosthesis-interposition left CCA after radical neck dissection of a parotid cancer left with infiltration of the CCA and radiation therapy 2010
- Fogarty-thrombectomy left CCA + stenting CCA / ICA 2015
- Minor stroke 2015

# Recorded Case: Recurrent stenosis left common carotid artery

## Risk Factors

- Former smoker
- Hypertention
- Diabetes mellitus type 2

# Angiography




# WIRION EPD System

- The WIRION system is comprised of a unique delivery monorail catheter that houses a pre-folded filter.
- It allows the physician to lock a stand-alone filter onto ANY standard 0.014" guide-wire; ANYWHERE along the wire.



# CGuard – Carotid Embolic Prevention System

MicroNet™ Technology



- Bio-stable mesh woven from a single strand of 20µm Polyethylene Terephthalate (PET)
- To trap and seal thrombus and plaque against
- Sutured to the distal and proximal crowns

