

**Case 16 Genoa 1:
male, 80 years (B-C)**

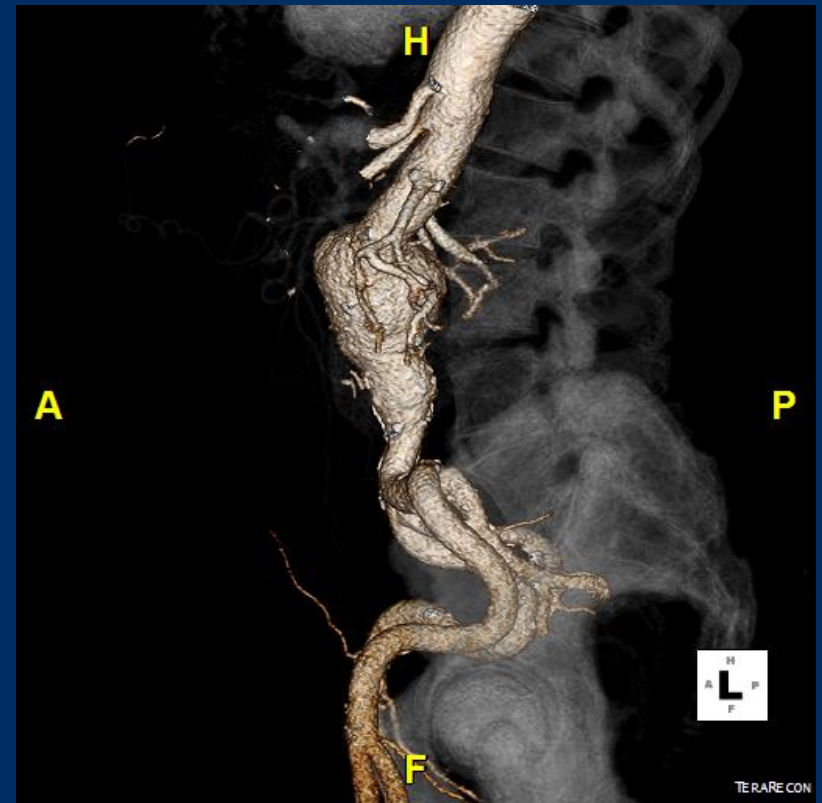
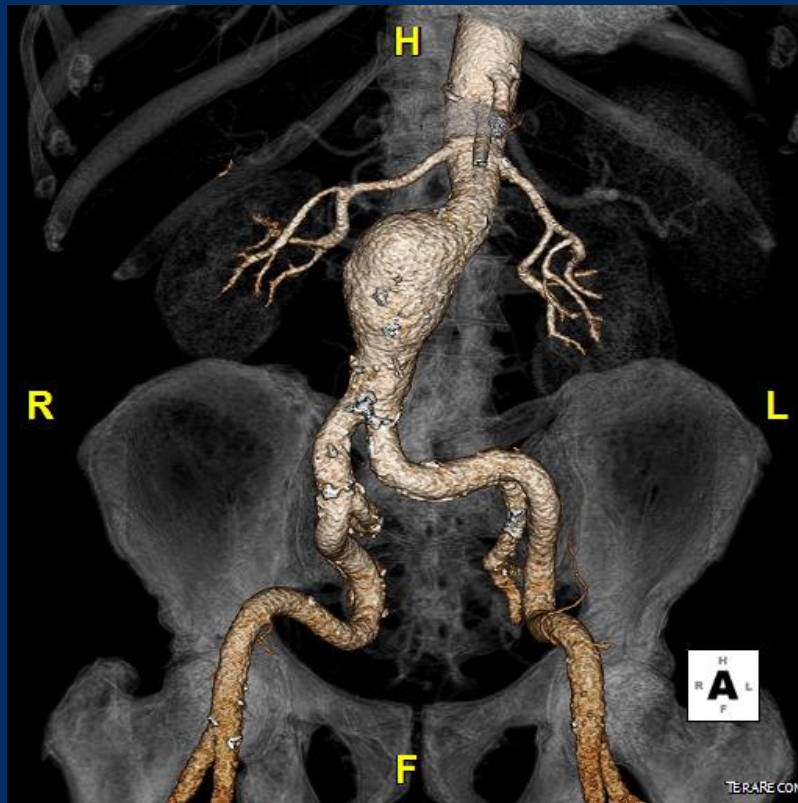
EVAR with Gore Excluder Endograft

**Operators: G. Pratesi, G. Spinella, S. Di Gregorio,
E. Visciglia**

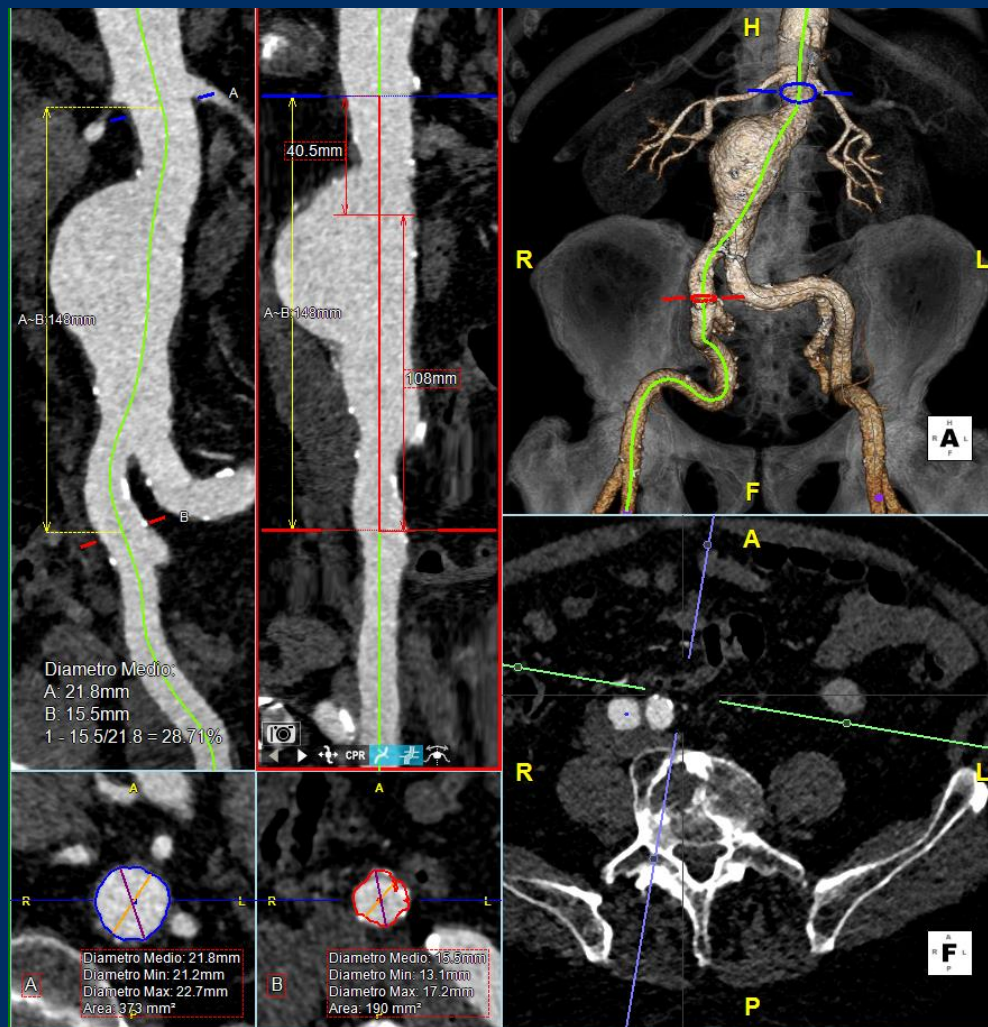
Case 16 Genoa 1: male, 80 years (B-C)

- **Clinical data:**
 - Rapidly growing asymptomatic infrarenal aortic aneurysm
(max. diam. 52 mm)
- **Risk Factor:**
 - Arterial hypertension
 - Dyslipidemia
 - former smoker
 - COPD
 - stage II CKD
 - previous bilateral inguinal hernioplasty

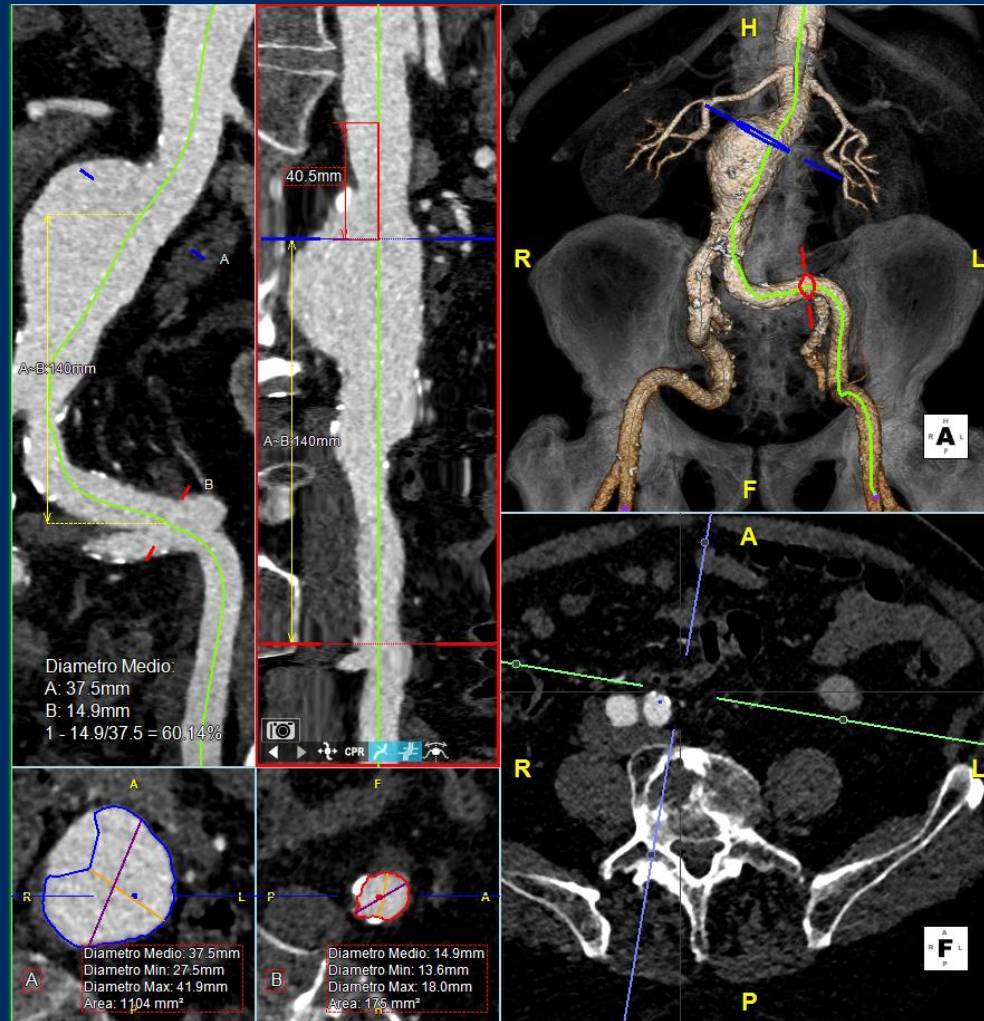
Case 16 Genoa 1: male, 80 years (B-C)



Case 16 Genoa 1: male, 80 years (B-C)



Case 16 Genoa 1: male, 80 years (B-C)



Case 16 Genoa 1: male, 80 years (B-C)

- **Procedural steps:**
 - **1. Bilateral percutaneous femoral access with Preclose Technique**
 - **2. CFA puncture under DUS guidance, 6F sheath, double Proglide 6F (Abbott), 11 F sheath on both sides**
 - **3. Change for Amplatz Super Stiff Wire and Gore Dryseal 16F sheath placement on R side**
 - **4. Advance long 5F Pigtail catheter over Terumo wire on L side for aortic angiogram and fusion mask registration**

Case 16 Genoa 1: male, 80 years (B-C)

- **Procedural steps:**
 - **5. Main body endograft deployment Gore Excluder endograft (cross-leg configuration) from R side**
 - **6. Gate cannulation, guidewire exchange, placement of Gore Dryseal 16F sheath and left limb deployment**
 - **7. Balloon angioplasty of the overlapping zones and final angiogram**
 - **8. Sheath removal and access closure with preimplanted Proglide**