



Best practices and technical learning on the on-label treatment of challenging necks:

The EXCeL Registry

Marc van Sambeek

Jenny Zwetsloot, Joep Teijink, Philippe Cuypers

Catharina Hospital Eindhoven
Eindhoven University of Technology

Disclosure

Marc van Sambeek

I have the following potential conflicts of interest to report:

Consulting and speakersfee

WL Gore & Associates

Medtronic

Unrestricted research grants

Medtronic

W.L Gore & Associates

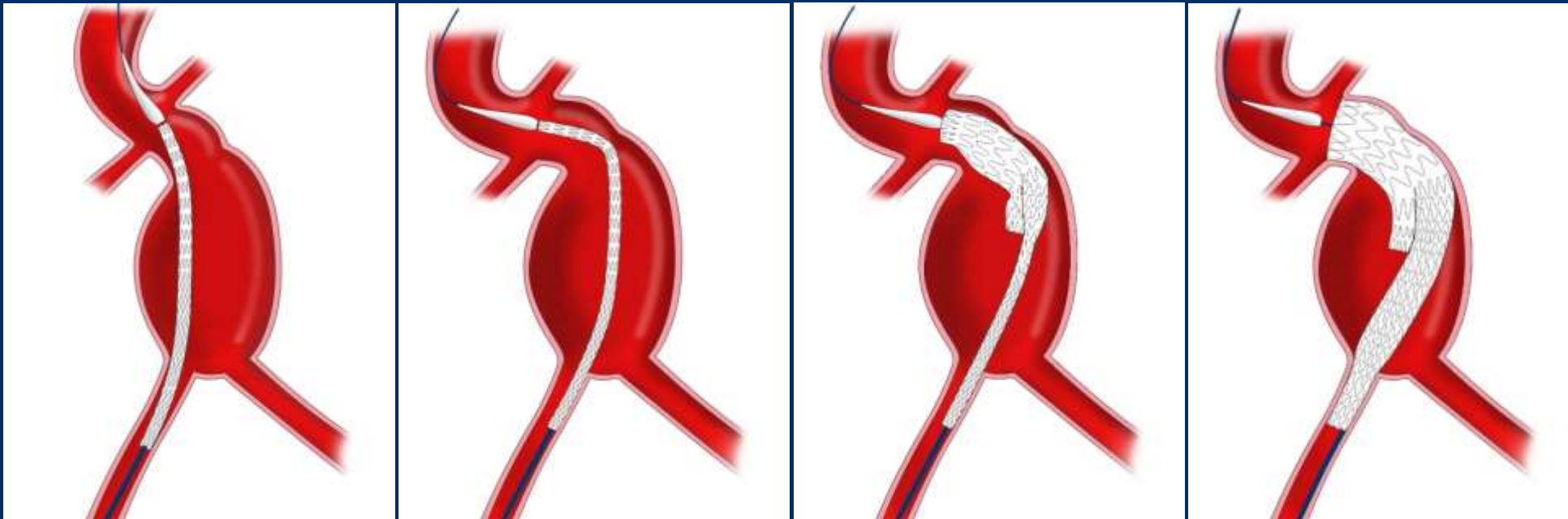
Philips Medical Systems

GORE® EXCLUDER® Conformable AAA Endoprosthesis



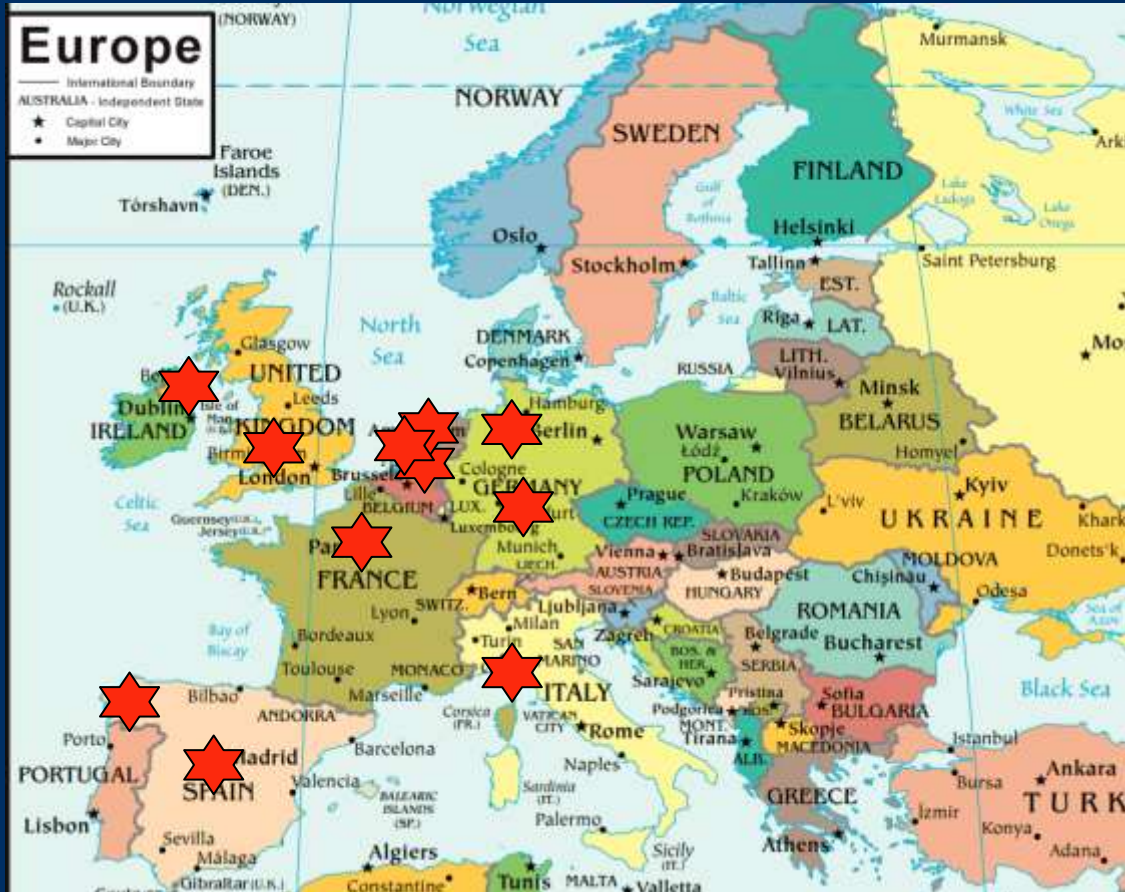The IFU anatomic criteria

- $\geq 15\text{mm}$ proximal neck length and $\leq 90^\circ$ proximal neck angulation
- $\geq 10\text{mm}$ proximal neck length and $\leq 60^\circ$ proximal neck angulation)

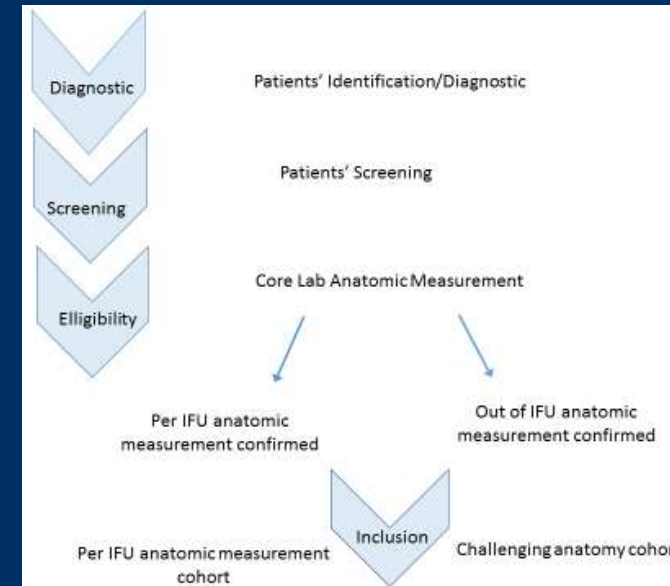


	> 15 mm neck length	10-15 mm neck length	5-10 mm neck length	< 5 mm neck length
< 60° neck angulation	Inside IFU	Inside IFU	Challenging anatomy	Extreme anatomy
60-90° neck angulation	Inside IFU	Challenging anatomy	Extreme anatomy	
> 90° neck angulation	Challenging anatomy	Extreme anatomy		

EXCeL Registry is a multi-center, post-market, non-interventional, non-randomized, single-arm, prospective observational study.



Follow-up 3 years



150 consented subjects from 10 high-volume sites across Europe will be included.

EXCeL Registry

Number of inclusion (N=90)*

Catharina Hospital Eindhoven	24
Rijnstate Hospital Arnhem	22
San Martino Hospital Genova	17
San Carlos Hospital Madrid	8
Complejo Hopitario de Orense	7
North Bristol NHS Trust	7
APHP Hospital Europeen Paris	3
ETZ Hospital Tilburg (Recently started)	2

* Data received by December 31 2020. Actual number of inclusion is higher

EXCeL Registry

Pre-operative

Number of patients	90
Age	76 years (56-94 years)
Gender	Female 16, Male 74
AAA diameter	59mm (26-90 mm) core-lab assessment
Neck length	29 mm (5-62 mm) core-lab assessment
Neck angulation	42 degrees (5-105 degrees) core-lab assessment

	> 15 mm neck length	10-15 mm neck length	5-10 mm neck length	< 5 mm neck length
< 60° neck angulation	57	3	2	
60-90° neck angulation	14	2		
> 90° neck angulation	3			

EXCeL Registry

Intra-operative

Percutaneous	74 (82%)
Re-positioning of device	52 (1-9 times)
Active control used	37 (1-3 times)
Proximal extension used	4
Covering renal artery	1 intentional coverage of accessory renal artery
Additional extensions	In 24 patients
Type I endoleak at completion angiogram	0

SAE 2

occlusion renal artery (not covered) => renal stenting
 rupture distal CIA => extension of endograft limb

EXCeL Registry	
30-days (N=65)	
Type I-b endoleak	1 (resolved by extension endograft limb)
Secondary intervention	1 (for Type II endoleak)
Migration	0
Death	0
Type II endoleak	12
Endoleak undetermined	2

Additional SAE 's 0

EXCeL Registry	
30-days – 1 year (N=32)	
Type I endoleak	0
Secondary intervention	0
Migration	0
Death	3
Type II endoleak	7
Endoleak undetermined	1

Death: * MI after CABG
* Respiratory insufficiency due COVID-19
* Unknown cause

EXCeL Registry

1 year - 2 years (N=14)

Type I endoleak	0
Secondary intervention	1 coiling IMA for Type II endoleak
Planned secondary intervention	1 PTA AIE (not EVAR related)
Migration	0

Conclusions

**EVAR continues to evolve as the treatment option for AAA
New generation devices will extend the applicability of EVAR**

**Preliminary results of the GORE® EXCLUDER® Conformable
AAA Endoprosthesis are promising**

The image features the word "LINIC" in a white, sans-serif font, centered horizontally. The text is overlaid on a dark blue background with two prominent, curved brush strokes. One stroke is a vibrant red, and the other is a golden-yellow, both curving from the bottom left towards the top right. The brush strokes have a textured, painterly appearance with visible bristles.

LINIC