

**Case 14 Zurich 3:
female, 27 years (F-R)**

**Right common iliac vein
reconstruction for postthrombotic
and pelvic congestion syndrome**

Operators: N. Kucher, E. Holy, A. Grigorean

Case 14 Zurich 3: female, 27 years (F-R)

Clinical data:

- Patient with severe postthrombotic syndrome right leg, with venous claudication and varicose veins due to iliofemoral DVT 2/2020**
- Pelvic congestion syndrome with right ovarian vein insufficiency**

Case 14 Zurich 3: female, 27 years (F-R)

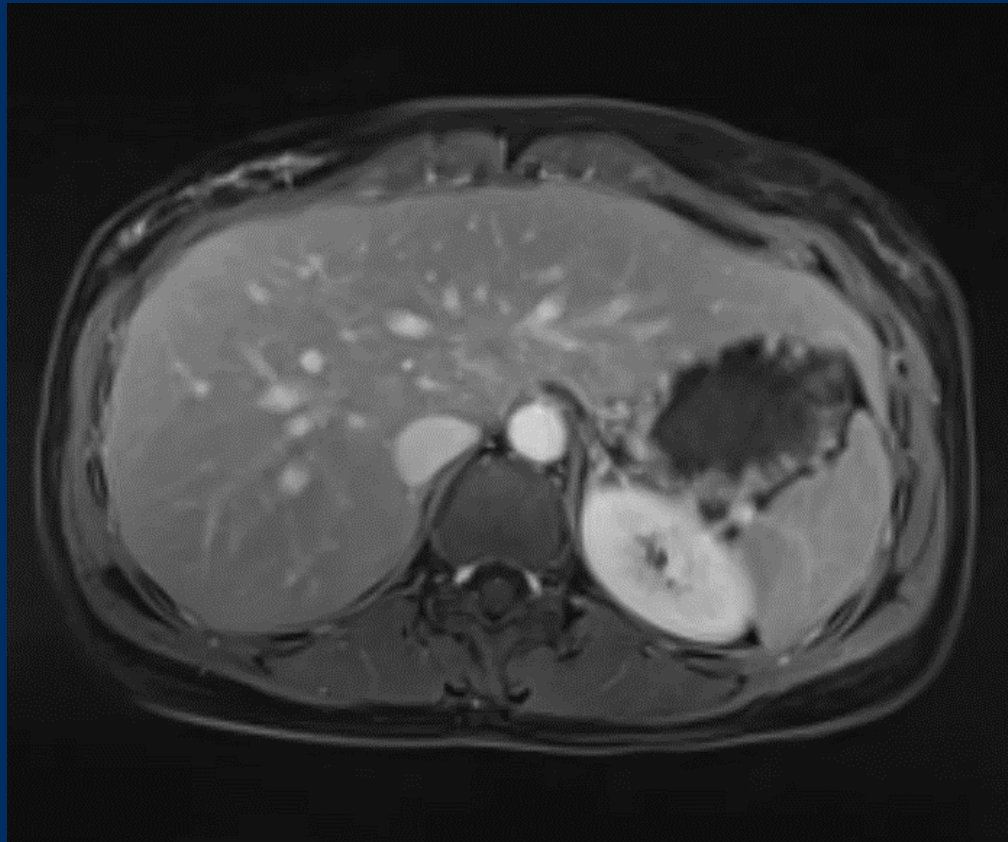
- **Risk factors:**
 - oral contraception
 - positive family history
- **Present state:**
 - venous claudication and varicose veins
right leg

Case 14 Zurich 3: female, 27 years (F-R)

- **Duplex and MRV:**
 - right iliac vein occluded
 - venous drainage via internal iliac vein and right ovarian vein

Case 14 Zurich 3: female, 27 years (F-R)

- MR Venography 18.12.2020:



Case 14 Zurich 3: female, 27 years (F-R)

- **Procedural steps:**
 - **1. Ultrasound-guided single venous access: right proximal femoral vein (10F), may use IJ access for pull-through maneuver**
 - **2. Angioplasty right common iliac vein 14 mm Atlas balloon**
 - **3. Reconstruction of right common iliac vein (Stent Venovo 14 or 16 mm)**
 - **May embolize right ovarian vein in second procedure**