

**Case 13 Zurich 2:  
female, 49 years (C-M)**

**Left common femoral vein  
reconstruction for postthrombotic  
syndrome with active venous leg  
ulcer post IV drug abuse**

**Operators: N. Kucher, E. Holy, A. Grigorean**

# Case 13 Zurich 2: female, 49 years (C-M)

- Clinical history:

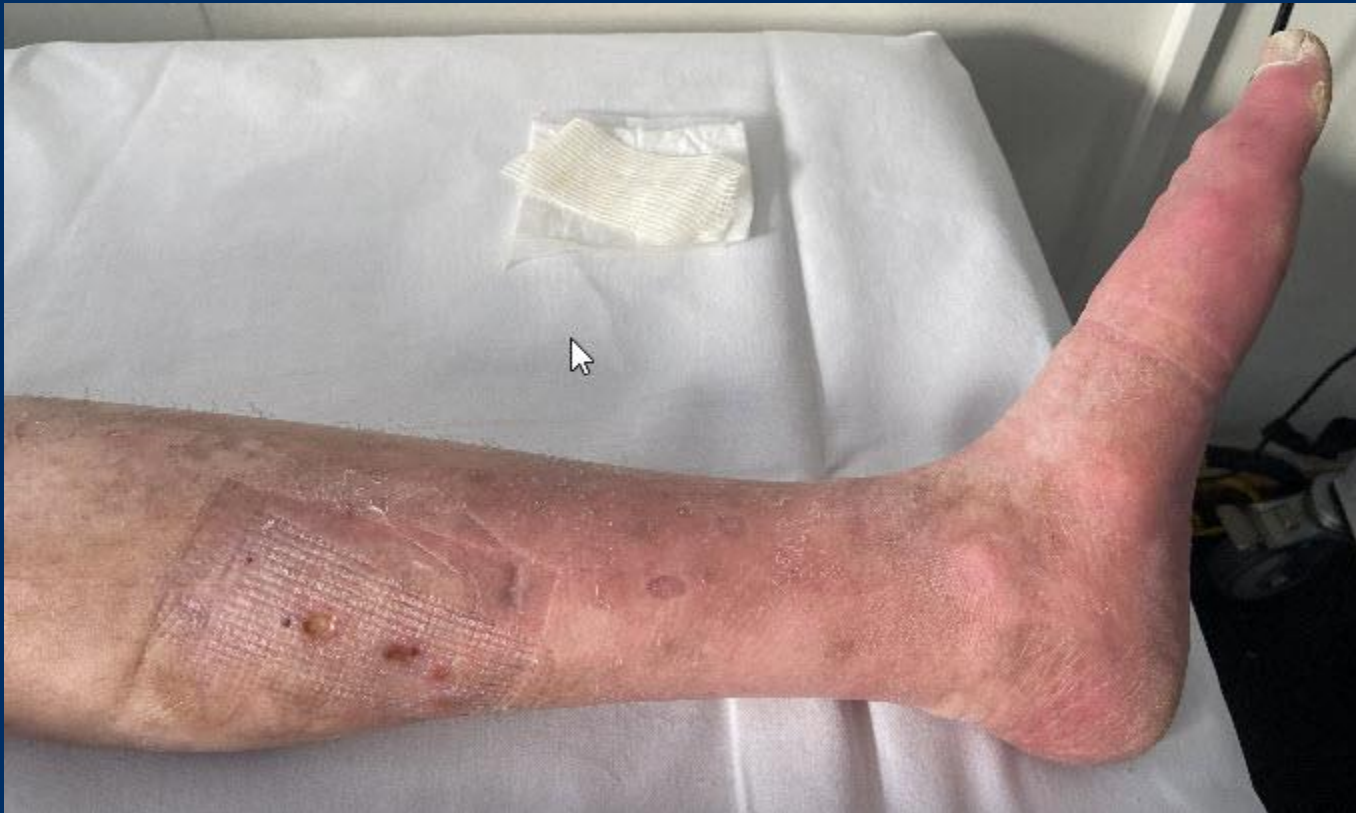- Methadon and Ritalin Substitution IV drug abuse, no IV-Drug consume since 5 years
- Recurrent episodes of femoral DVT and femoral abscess
- Recurrent venous leg ulcer bilaterally, left persisting
- Polytrauma with multiple vertebral body fracture after downfall from 4 meters 2011

# Case 13 Zurich 2: female, 49 years (C-M)

- **Current medical problems:**
- **Postthrombotic syndrome with venous claudication**
- **Venous leg ulcer left**
- **Bilateral varicose veins**

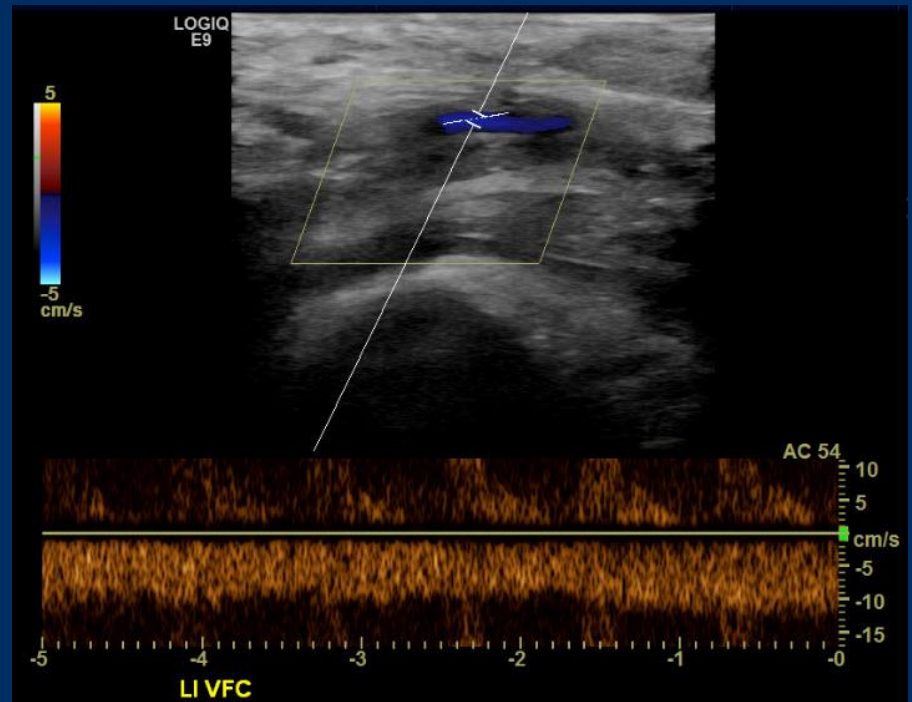
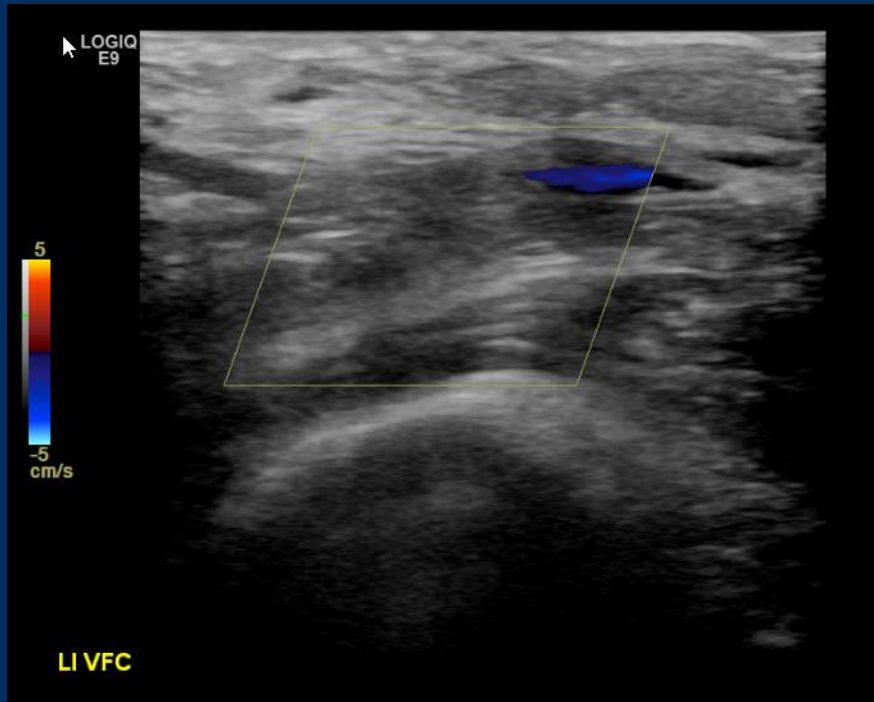
# Case 13 Zurich 2: female, 49 years (C-M)

- Clinical examination 17.12.2020



# Case 13 Zurich 2: female, 49 years (C-M)

- Duplex Sonography 17.12.2020



# Case 13 Zurich 2: female, 49 years (C-M)

- **Interpretation:**
  - **Severe PTS with active venous leg ulcer due to IV drug induced occlusion of both common femoral veins**

# Case 13 Zurich 2: female, 49 years (C-M)

- **Procedural steps:**
  - **1. Local anaesthesia, analgosedation, ultrasound-guided single venous access: left proximal femoral vein (10F), provisional IJ access for pull through maneuver**
  - **2. Wire crossage, angioplasty femoral and iliac veins (Atlas 12 mm), may use CTO techniques or cutting ballons (8mm)**
  - **3. Reconstruction of common femoral and iliac veins (Stent: Venovo or Blueflow 12 or 14 mm)**