

# Pelvic Congestion Syndrome Case Discussions

Dr. D. Beckett

Royal Bournemouth Hospital

The Whiteley Clinic, London

# Disclosure

Speaker name:

Dr. David Beckett

I have the following potential conflicts of interest to report:

- x Consulting
- Employment in industry
- Stockholder of a healthcare company
- Owner of a healthcare company
- Other(s)

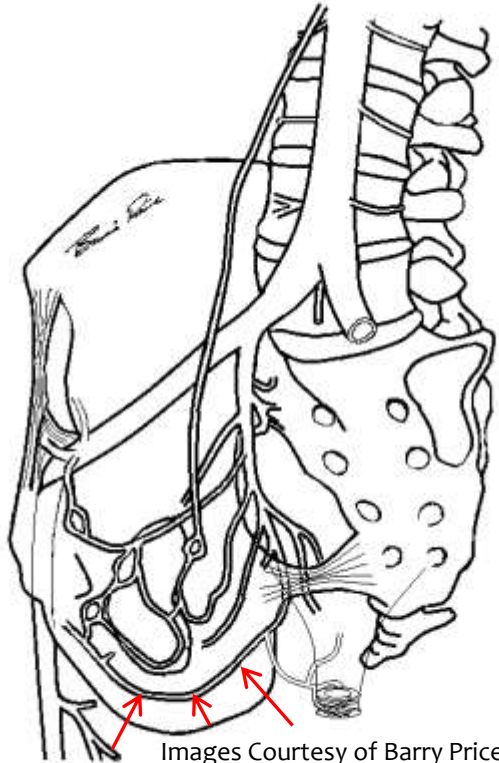
# Scope of Presentation

- \* Anatomy
- \* Critical issues in Diagnosis
- \* Cannulisation and visualisation
- \* Complications

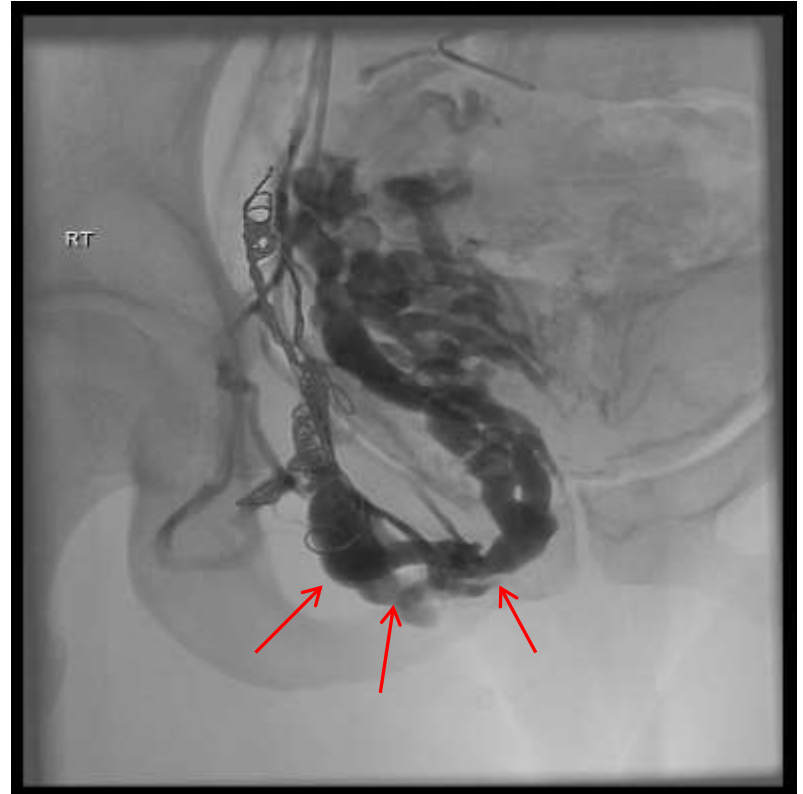
# Anatomical Considerations in Pelvic Vein Embolisation

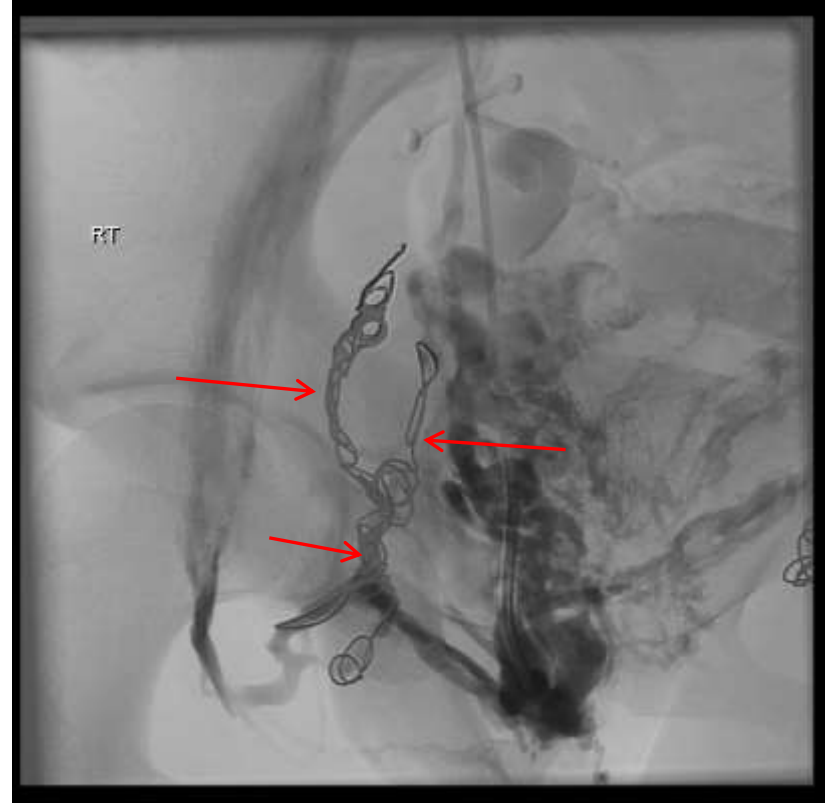
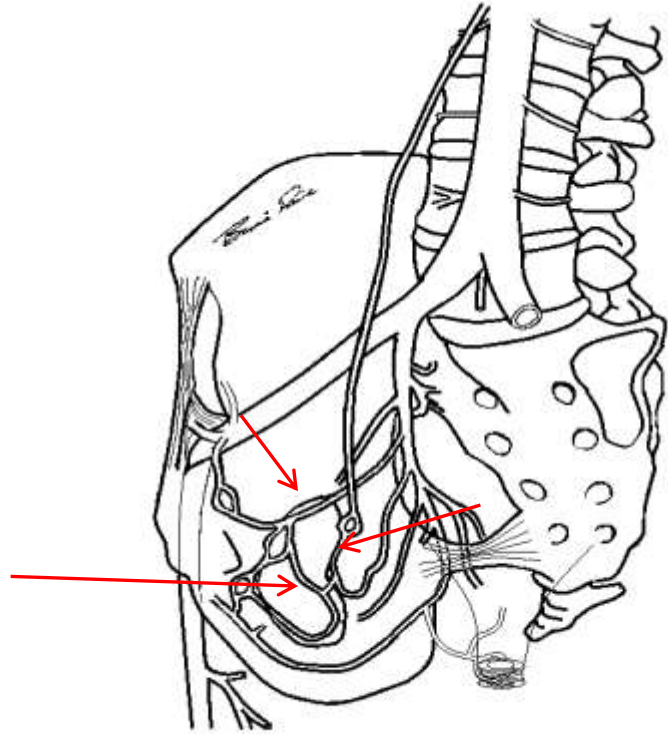


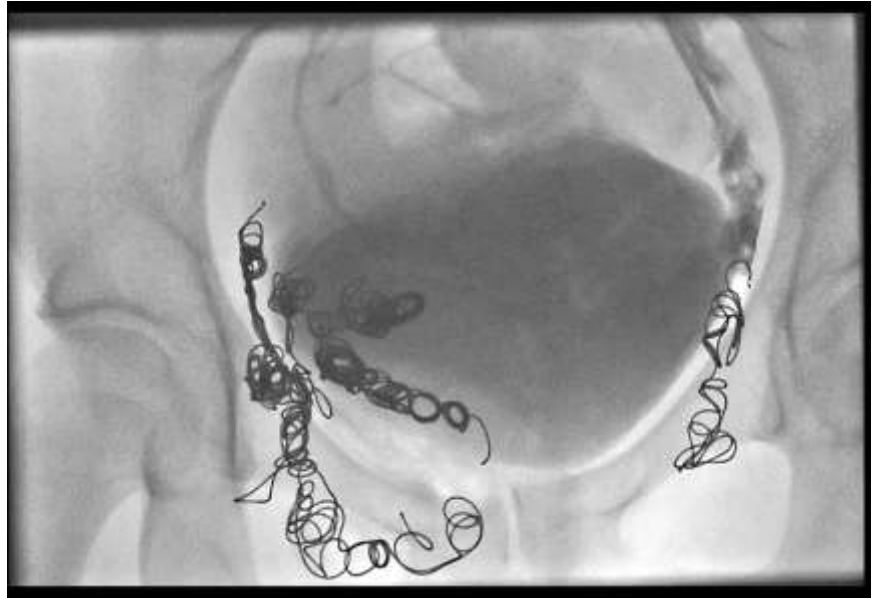
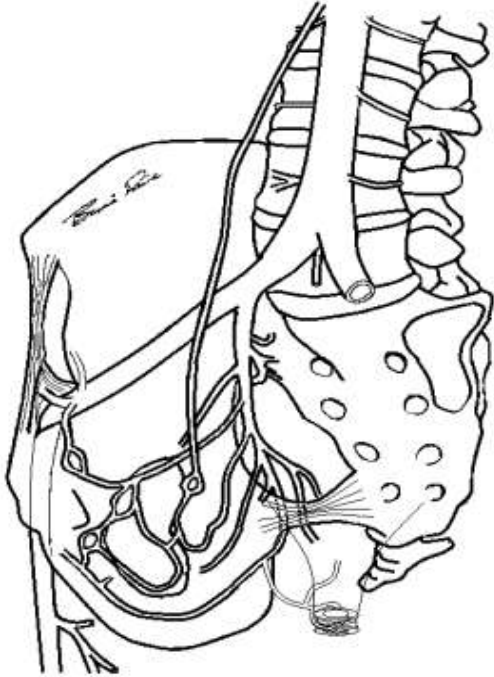
Standard Ovarian  
venous anatomy



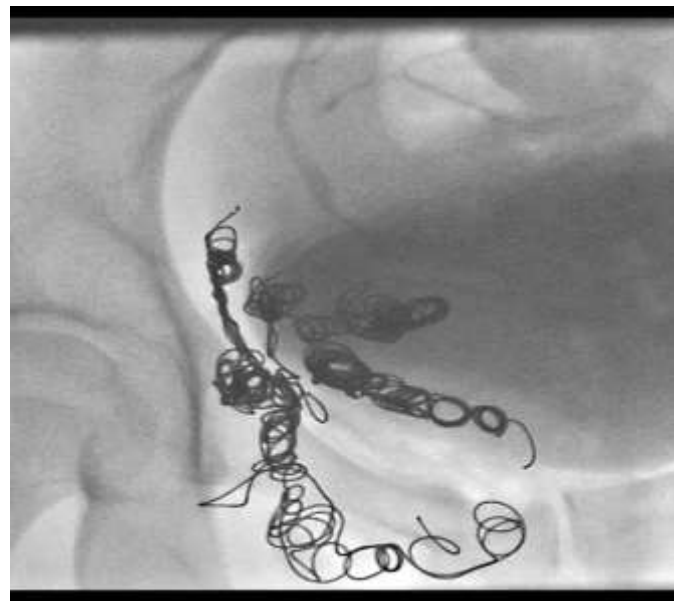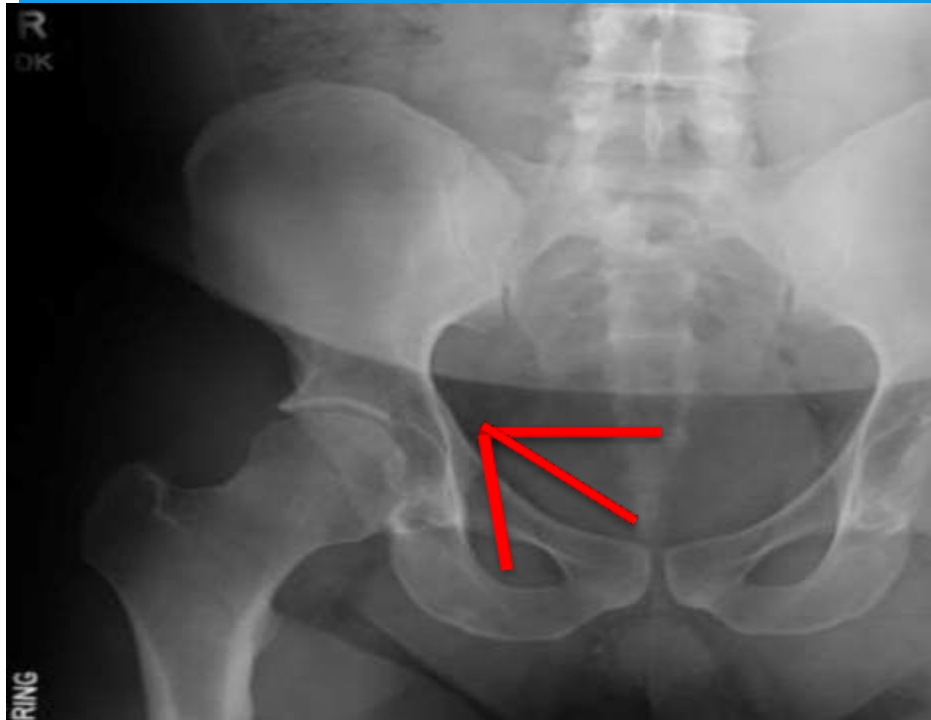
Images Courtesy of Barry Price

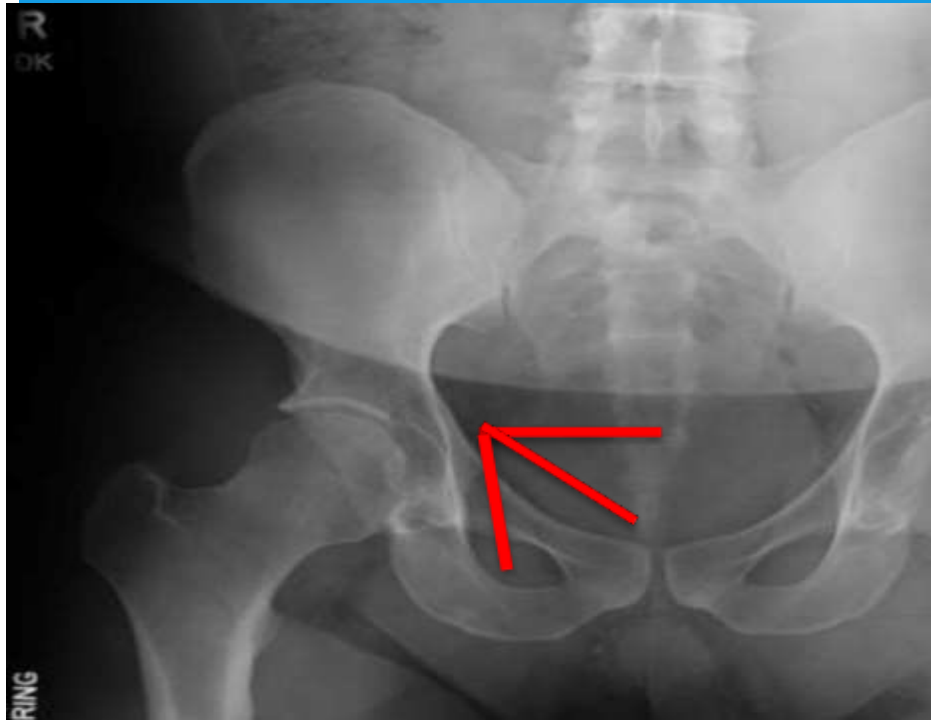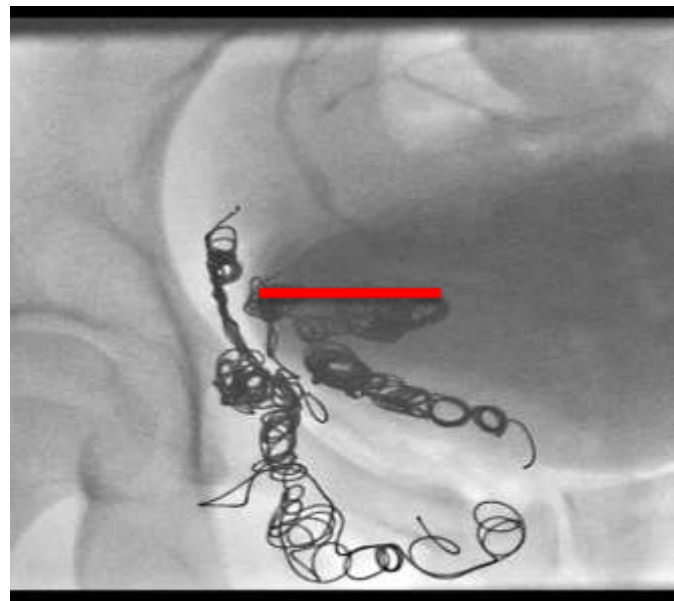


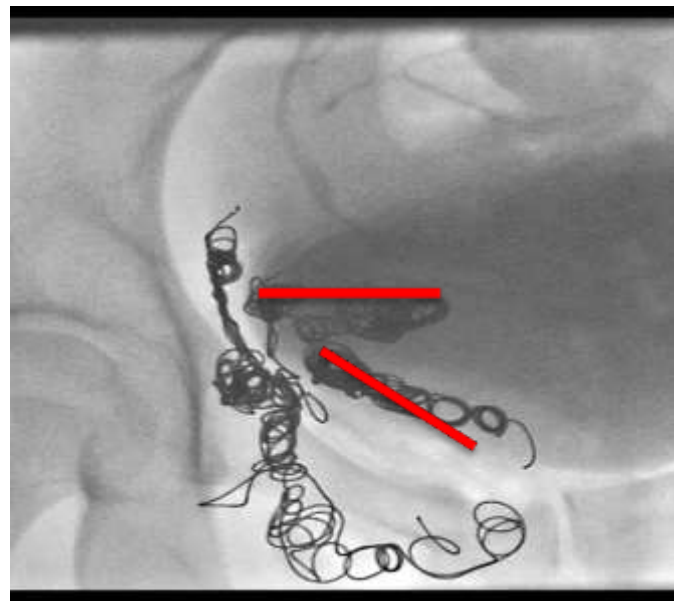
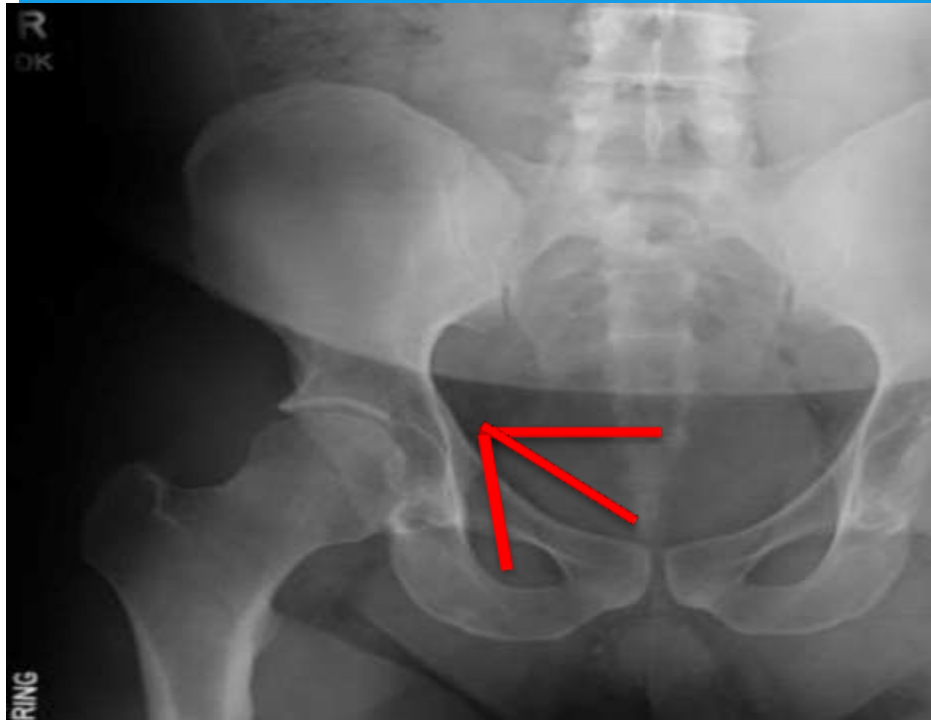


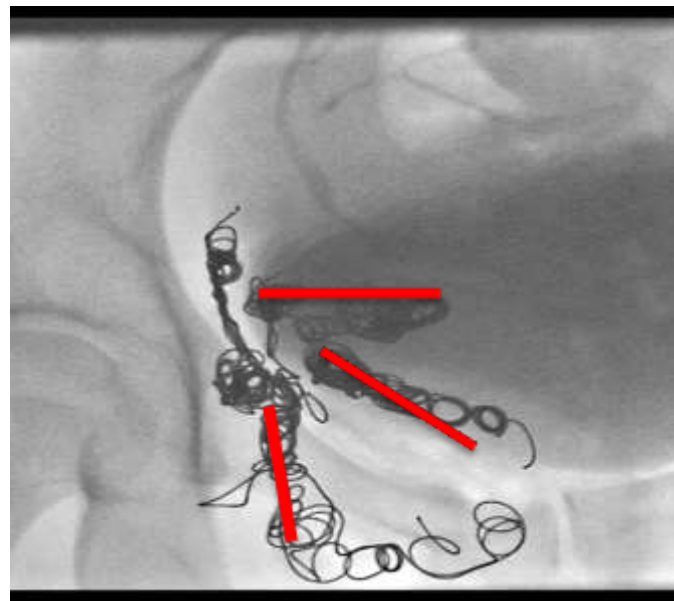
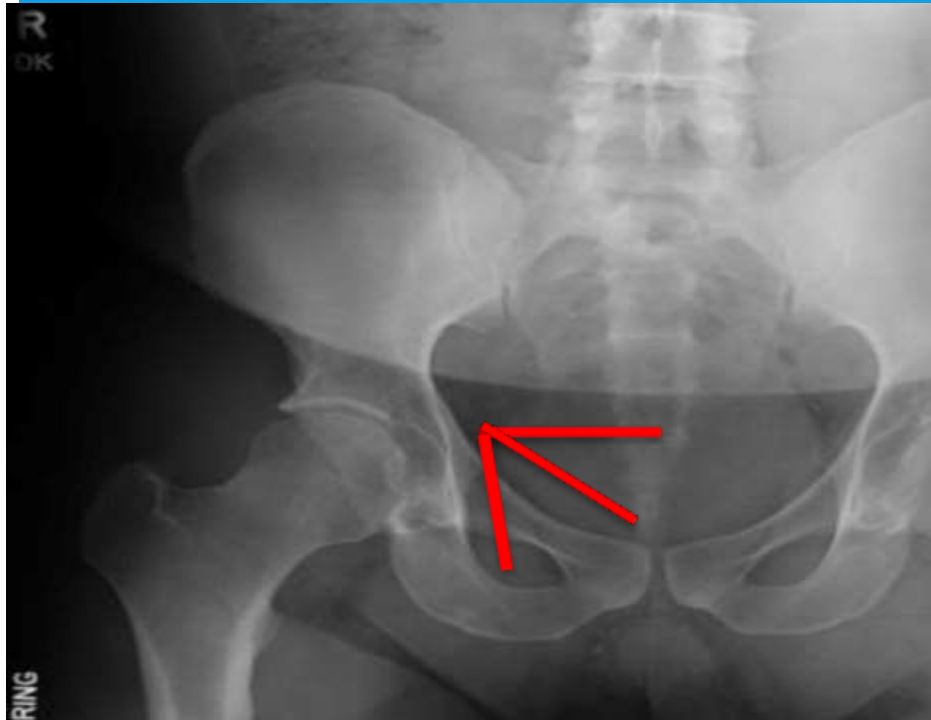




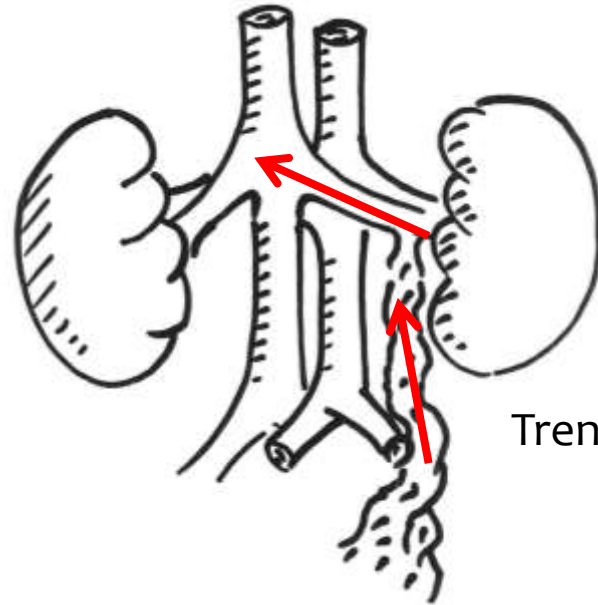
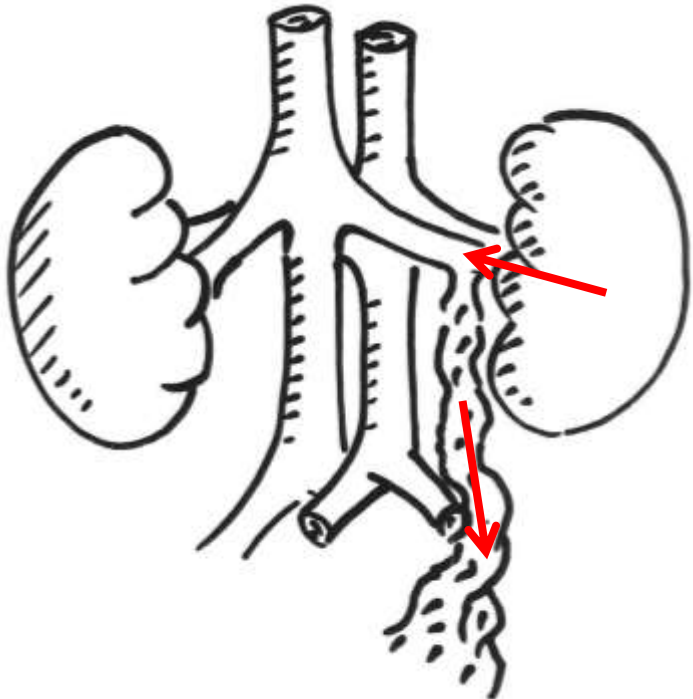







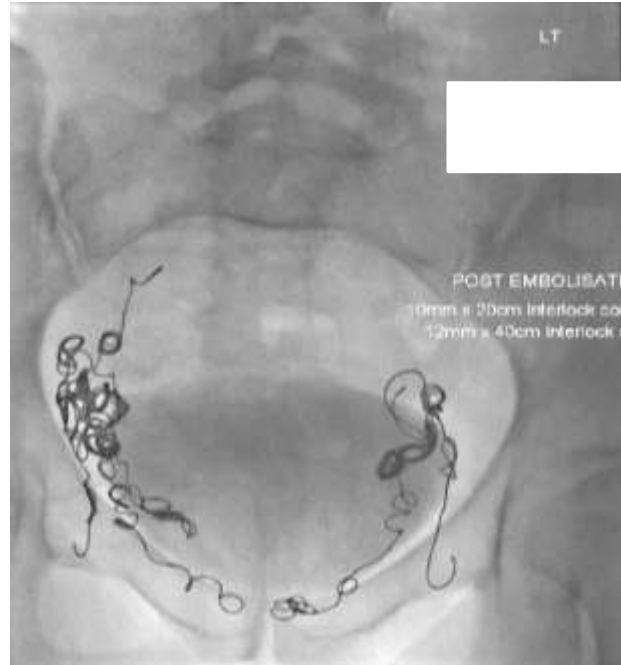
# Critical Issues in Diagnosis Exclusion of Compression



Trendelenburg

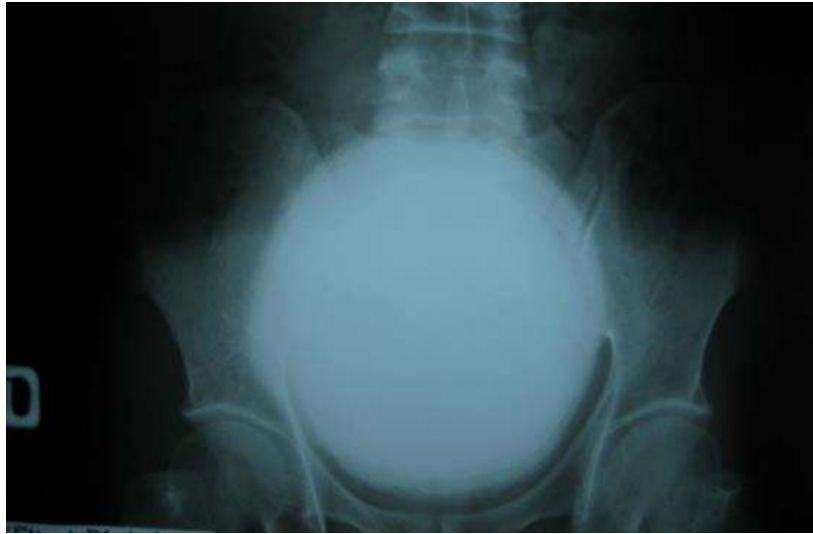# Tips and Tricks/ Case Discussions



# Equipment

- \* 6 F Sheath
- \* MPA
- \* Sim 2
- \* Stiff Hydrophilic wire
- \* Snare
- \* Microcatheter
- \* Cook Nester/Retractor Coils
- \* STS 3%

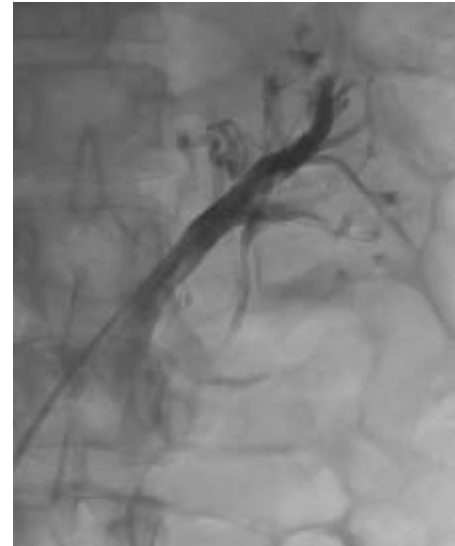
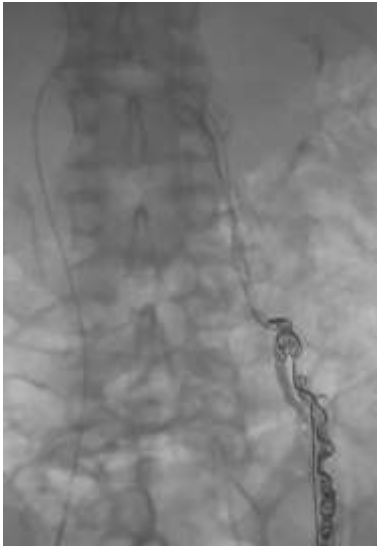




Urinary Catheter?

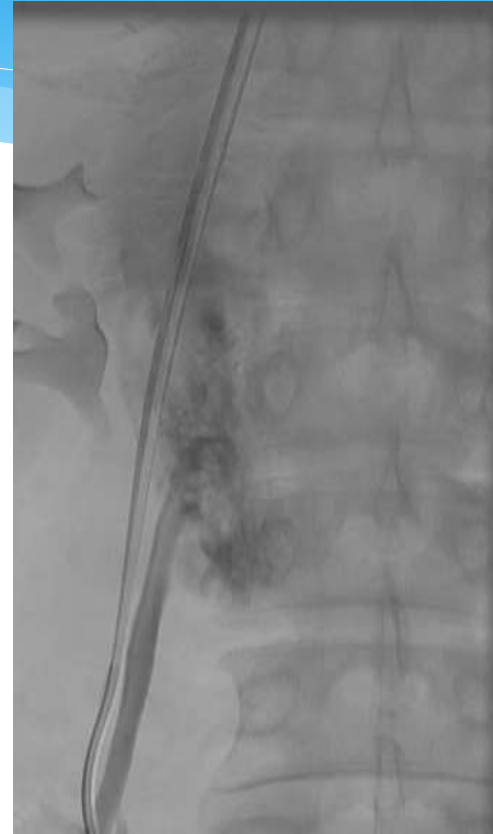# Access and Cannulation

## \* Femoral vs Jugular



# Access and Cannulation

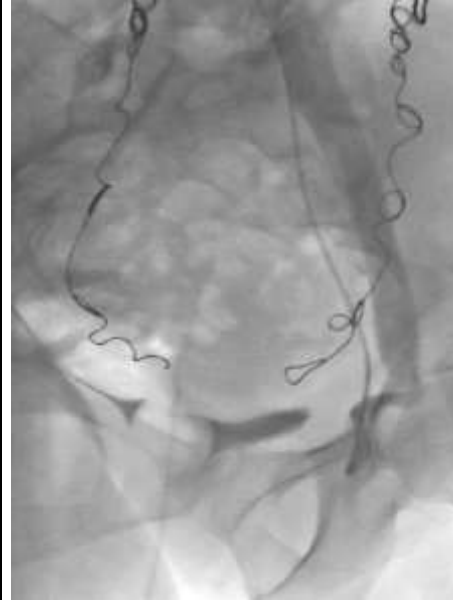
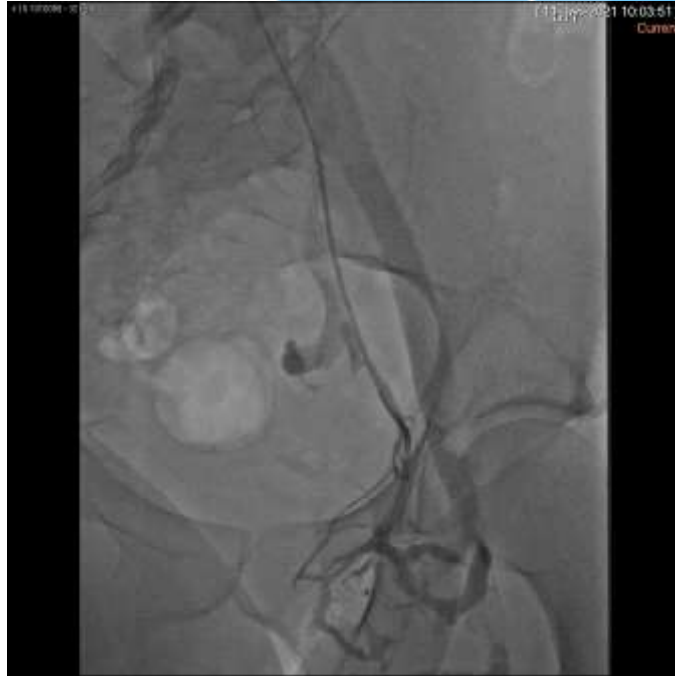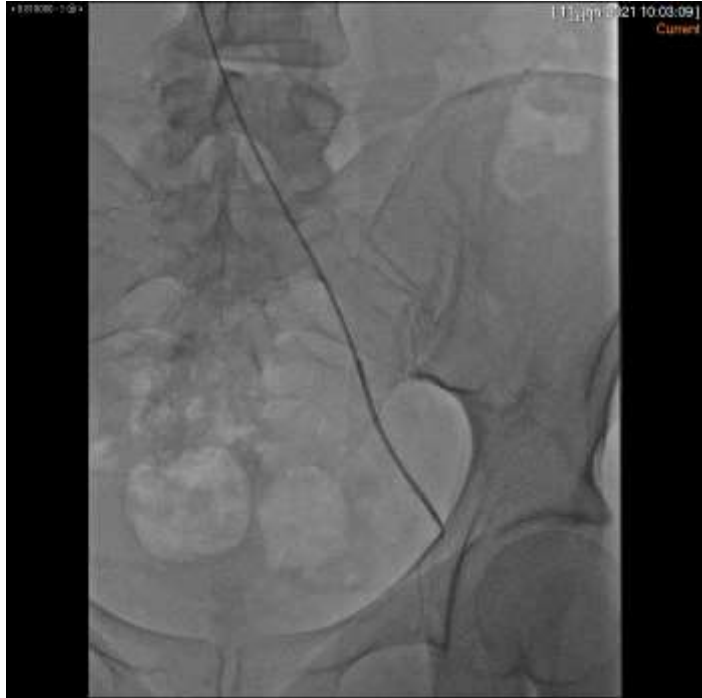- \* Femoral vs Jugular



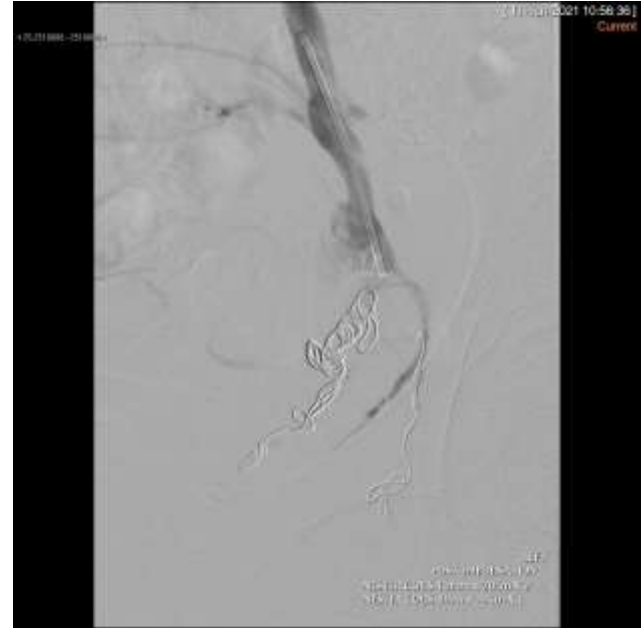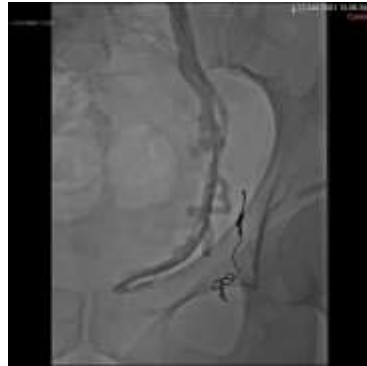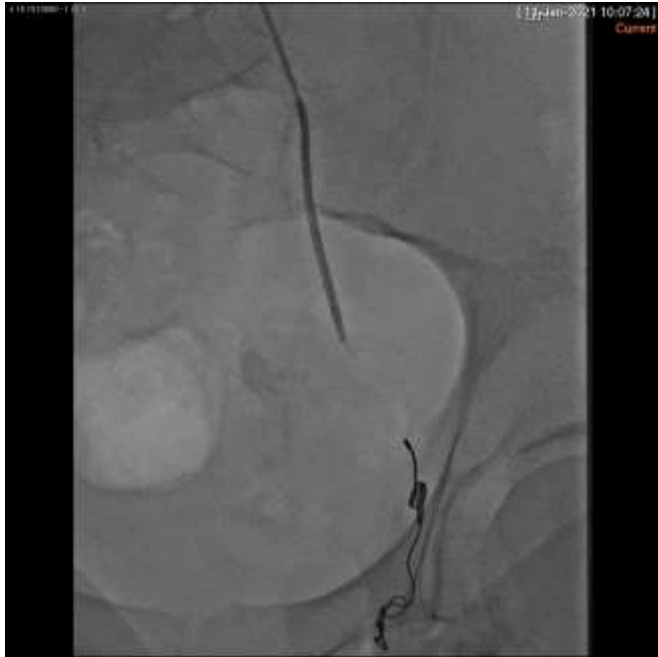# Iliac Vein Cannulation

- \* Obturator
- \* Pudendal
- \* Parauterine/Arcuate

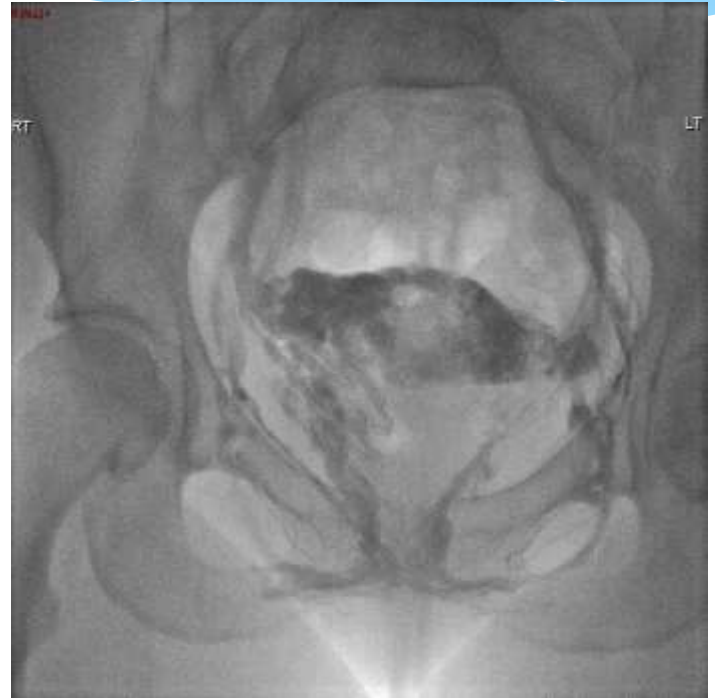
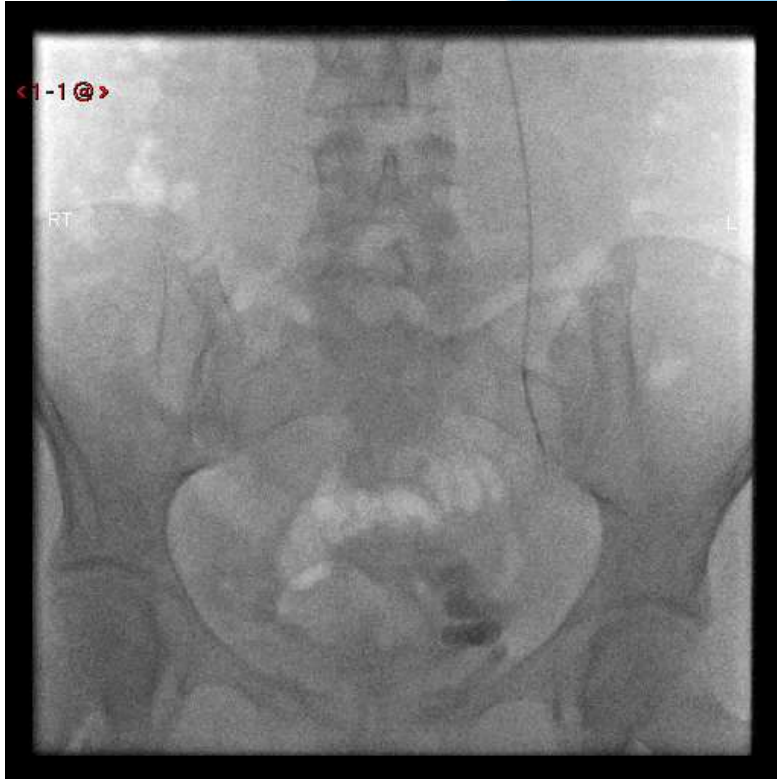
# Obturator Cannulation



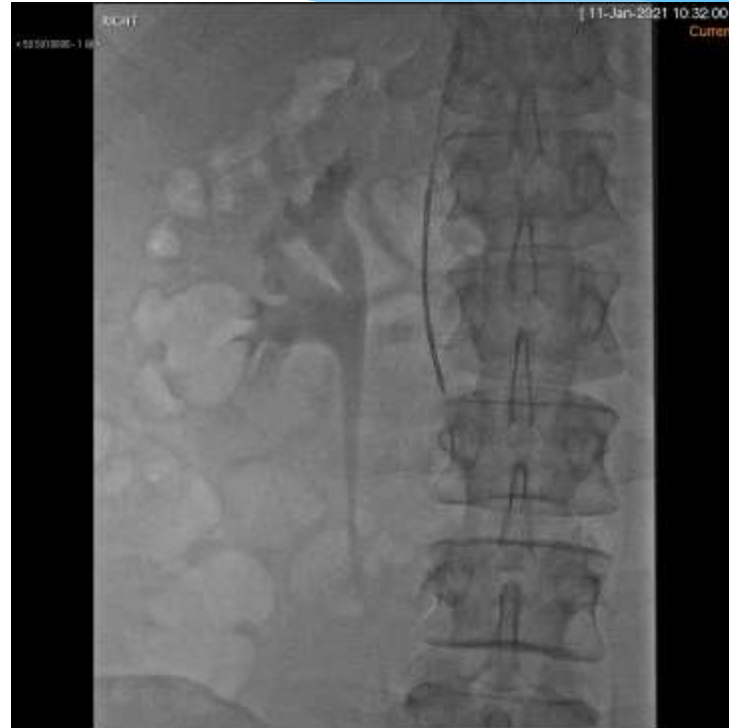# Pudendal Cannulation



# Cross Opacification

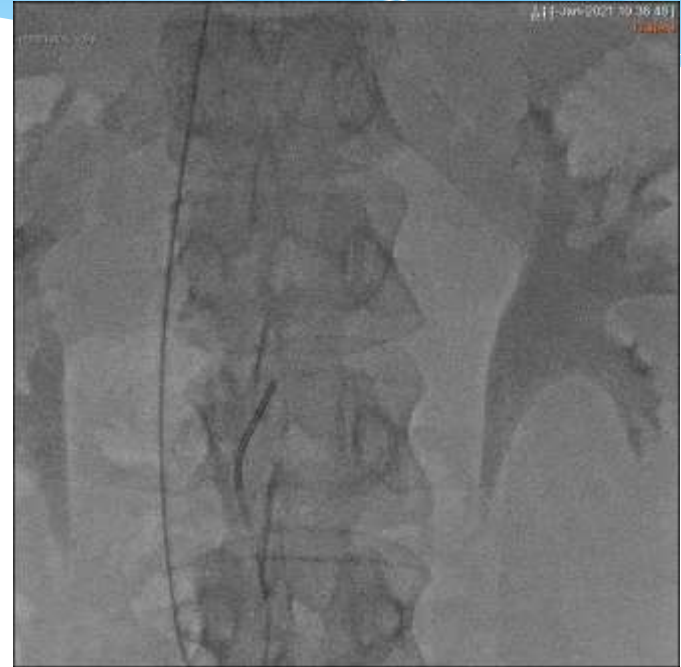
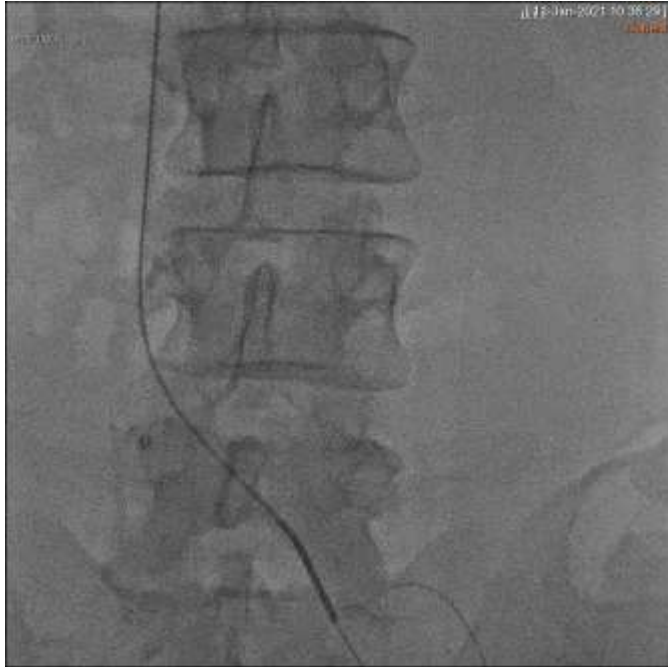
# Ovarian Cannulation



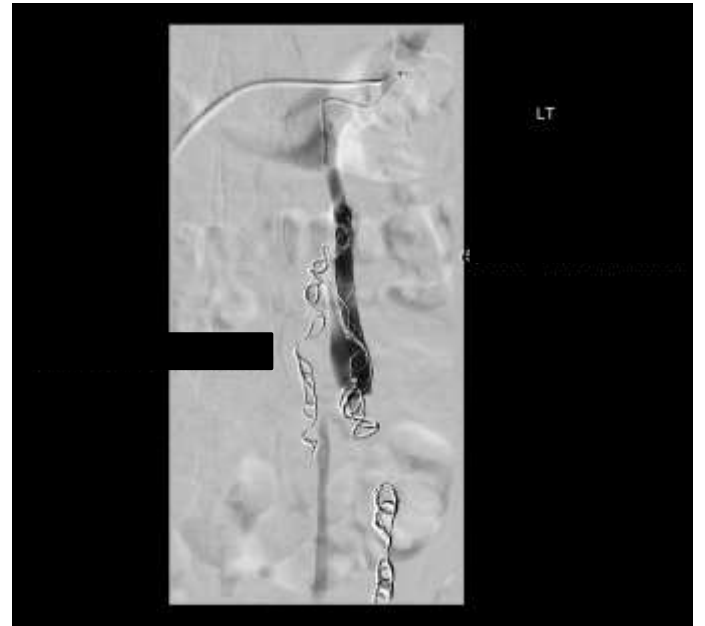
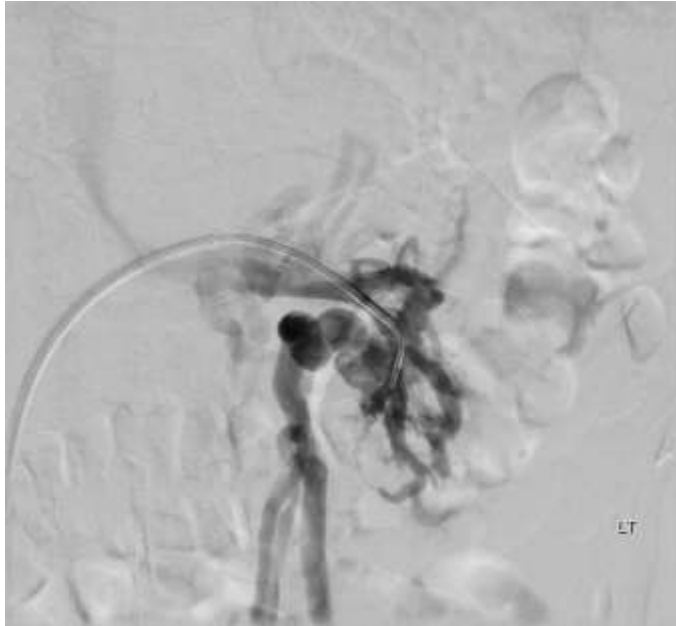

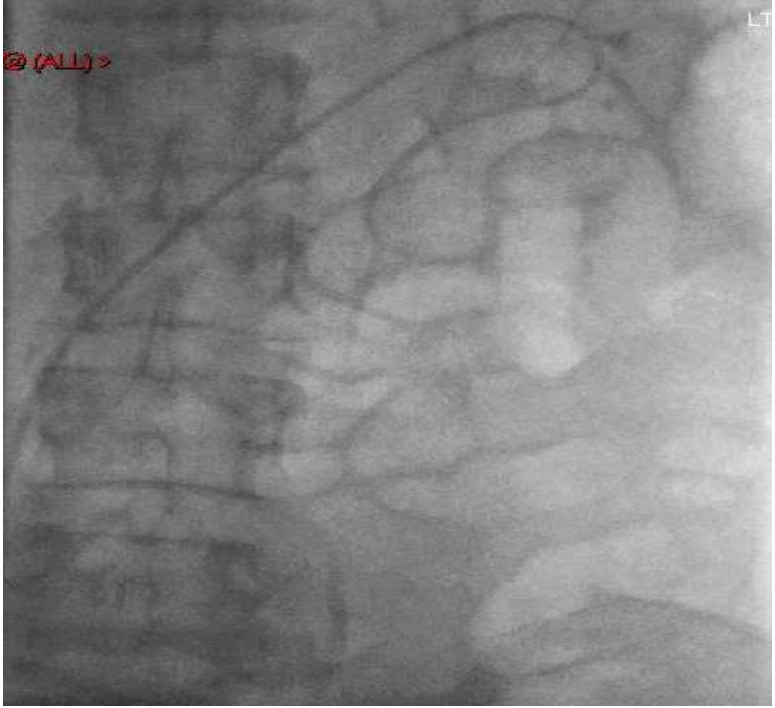# SIM 2 Cannulation



# Challenges

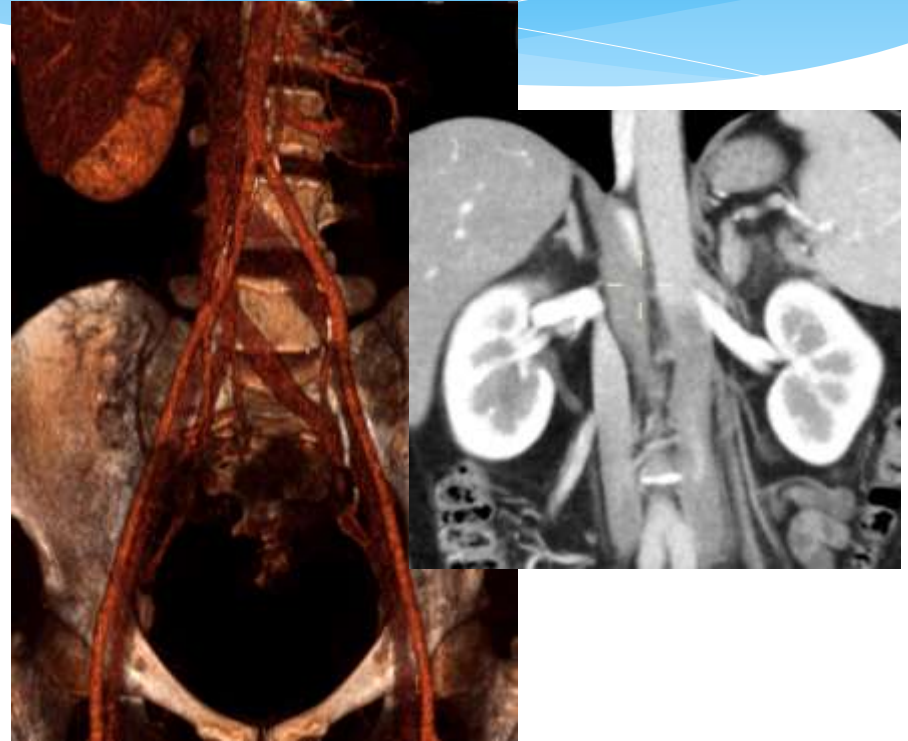
# Segmental renal Supply





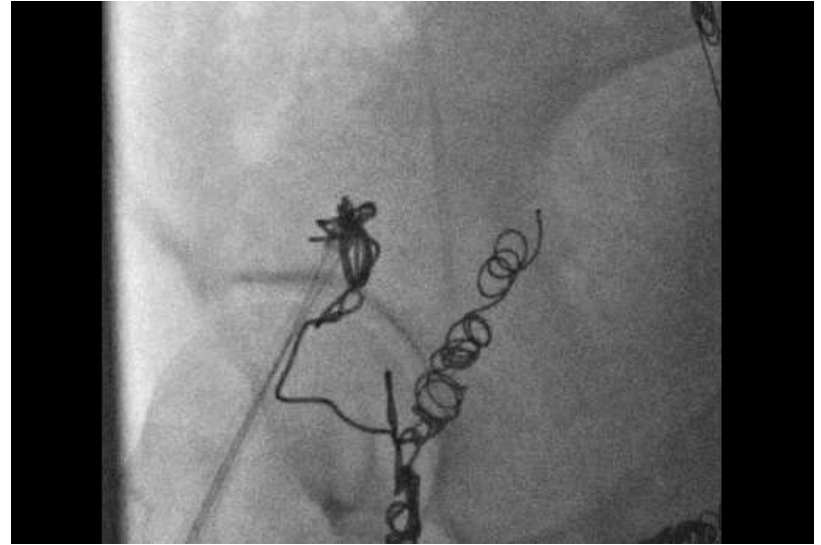
# Anatomical Variation

- \* Duplex IVC
- \* Aberrant iliac vein supply
- \* Segmental renal vein with proximal ovarian atrophy



# Complications

- \* Coil migration
- \* Post embolisation syndrome
- \* Coil Allergy
- \* Increasing pelvic pain
  - \* ?Neurogenic



# Thank You

[drdavidbeckett@gmail.com](mailto:drdavidbeckett@gmail.com)