

**Case 11 Berlin 1:  
male, 72 years (G-R)**

**Multifocal calcified SFA lesions left in  
a patient with history of heavy  
smoking**

**Operators: R. Langhoff, M. Boral**

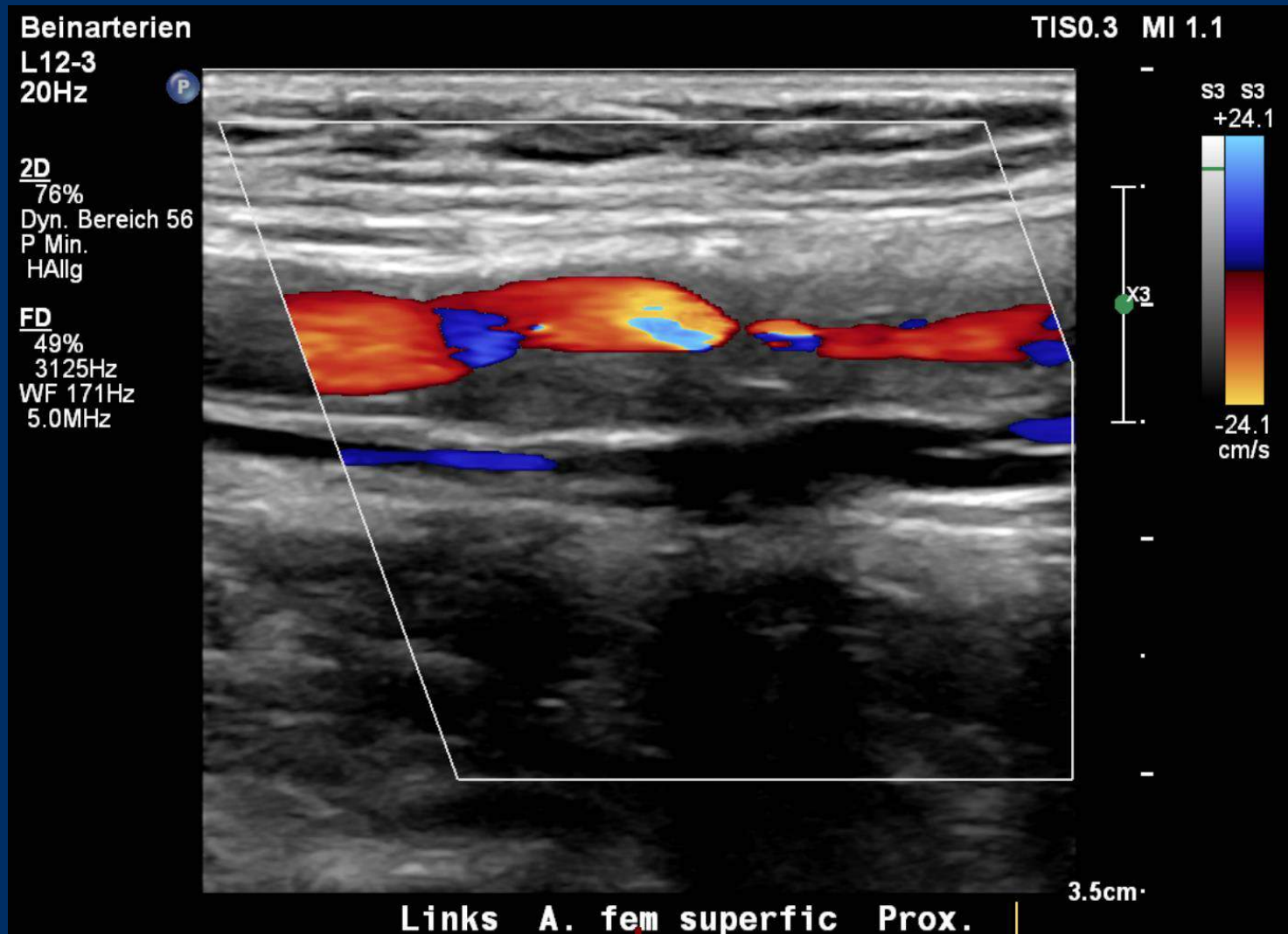
# **Case 11 Berlin 1: male, 72 years (G-R)**

- **Clinical data:**
  - **PAOD Rutherford 3 left**
  - **walking capacity 30 m**
  - **ABI left 0.38 after treadmill examination**
  - **2015 aorto-biiliac-bypass**
  - **lumbar spinal stenosis**
  - **long QT syndrom**

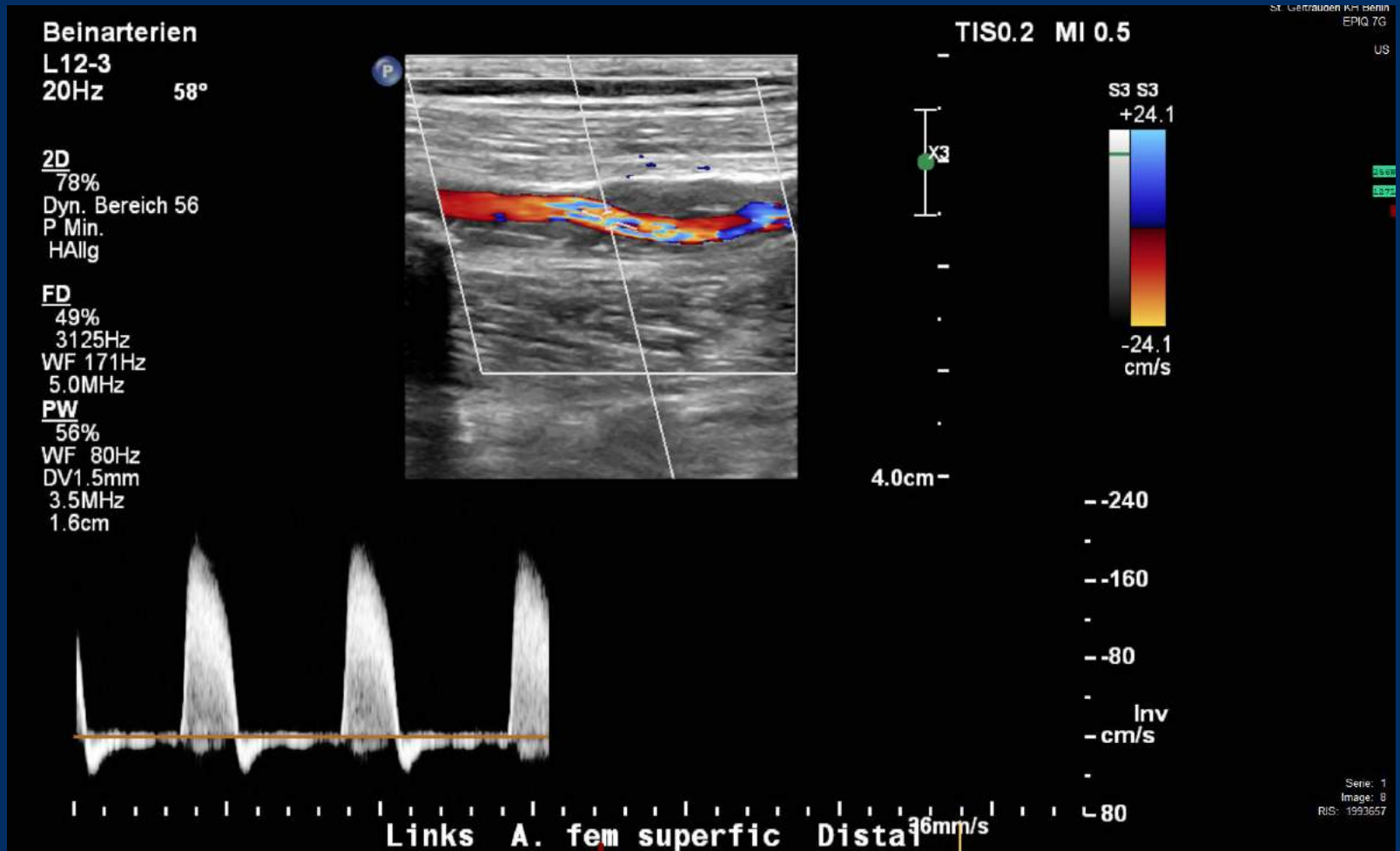
# Case 11 Berlin 1: male, 72 years (G-R)

- **Risk factors:**
  - hypertension
  - hyperlipidemia
  - heavy smoker
  
- **Duplex:**
  - multifocal highly calcified lesions

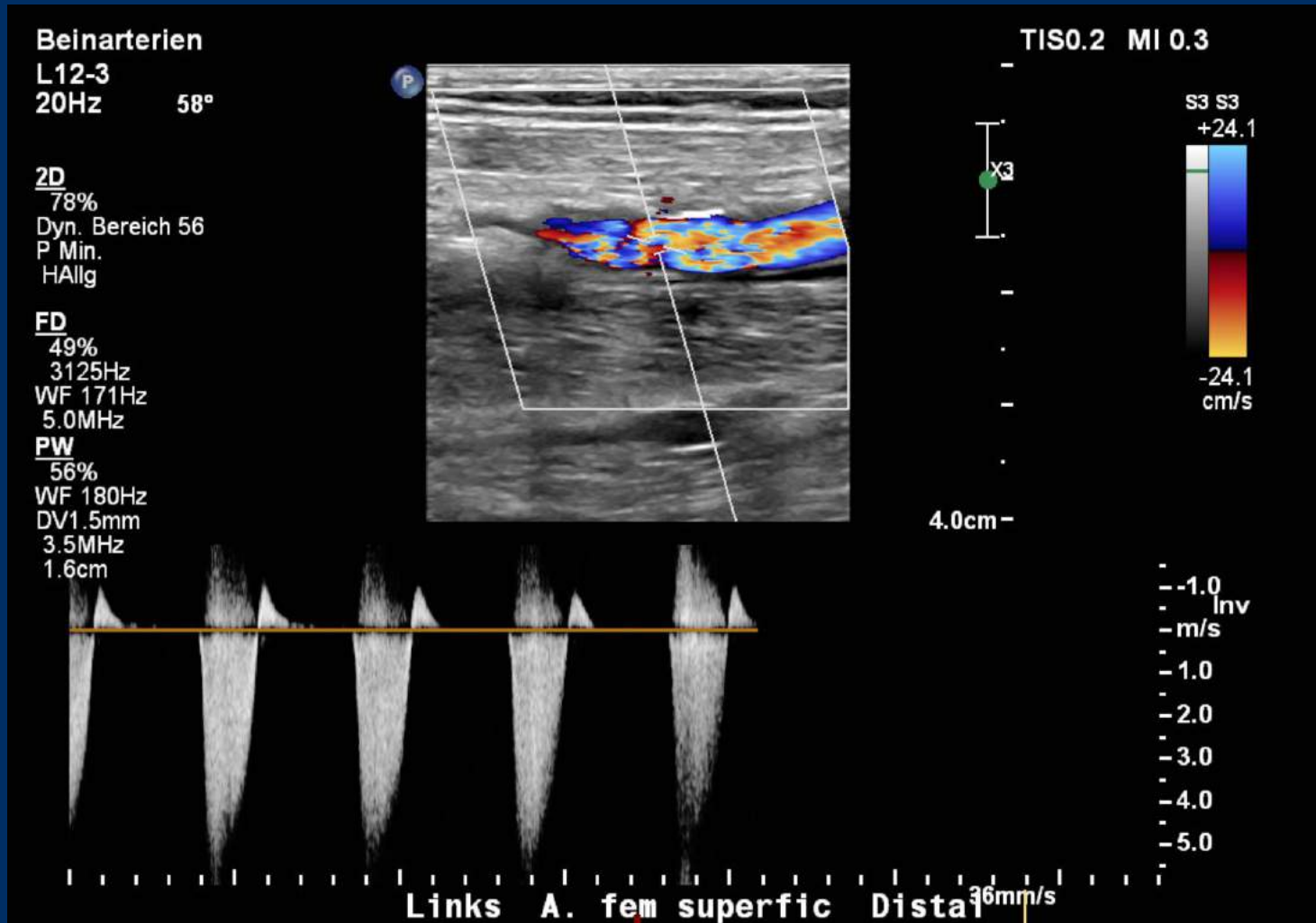
# Case 11 Berlin 1: male, 72 years (G-R)



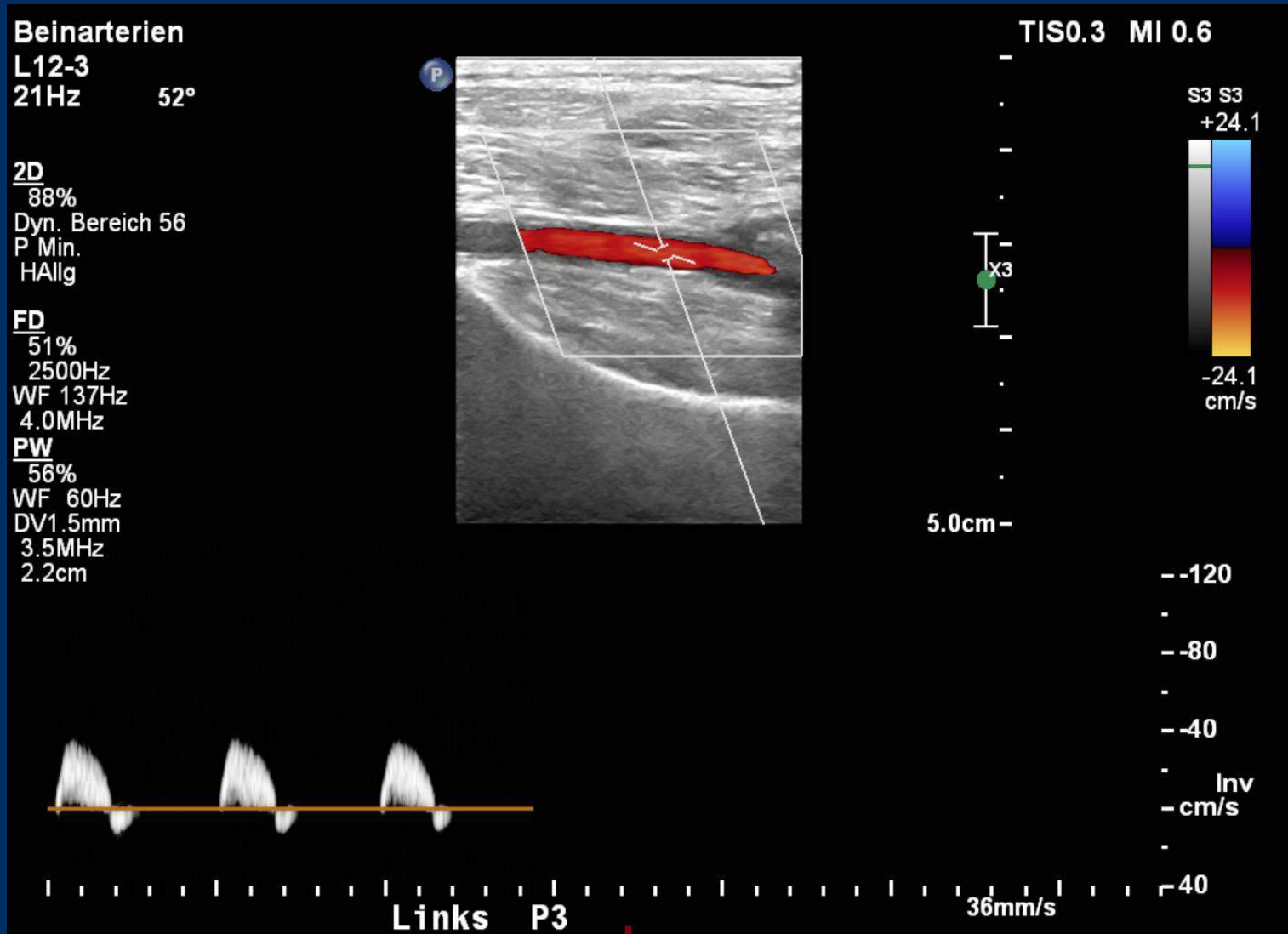
# Case 11 Berlin 1: male, 72 years (G-R)



# Case 11 Berlin 1: male, 72 years (G-R)



# Case 11 Berlin 1: male, 72 years (G-R)



# Case 11 Berlin 1: male, 72 years (G-R)

- **Procedural steps:**
  - 1. Antegrade access left CFA- 7F sheath (Terumo)
  - 2. Recanalisation- 0.018 Advantage wire (Terumo)
  - 3. Support catheter- MPA-1 catheter (Cordis)
  - 4. SpiderFX™ embolic protection device (0.014 wire) (Medtronic)
  - 5. Vessel preparation - HawkOne 7 F- device (Medtronic)
  - 6. PTA- MagicTouch PTA (two-ballons) (Concept medical)"
  - 7. remove filter over the MPA-1 catheter
  - 8. Manual compression after removing the sheath or vessel closure with Angioseal (Terumo)