



LINC, 27.01.2021

Deep Dive Session:  
Innovations and new techniques in embolization therapies

# New therapeutic options in osteoarthritis

## Transarterial periarticular embolization (TAPE)

M. Katoh

Diagnostic and Interventional Radiology  
Helios Hospital Krefeld



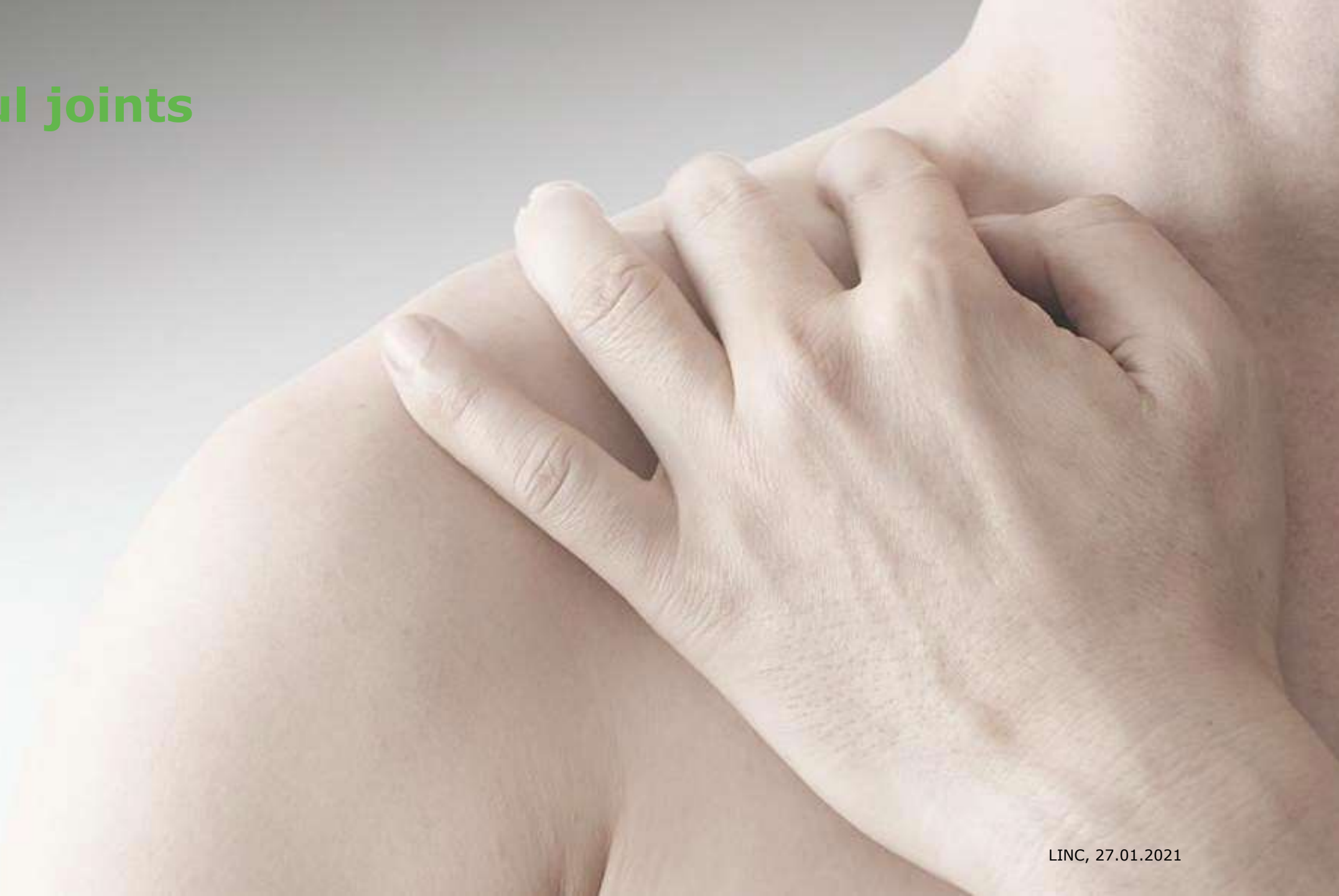# Disclosure

Speaker name: Marcus Katoh

I have the following potential conflicts of interest to report:

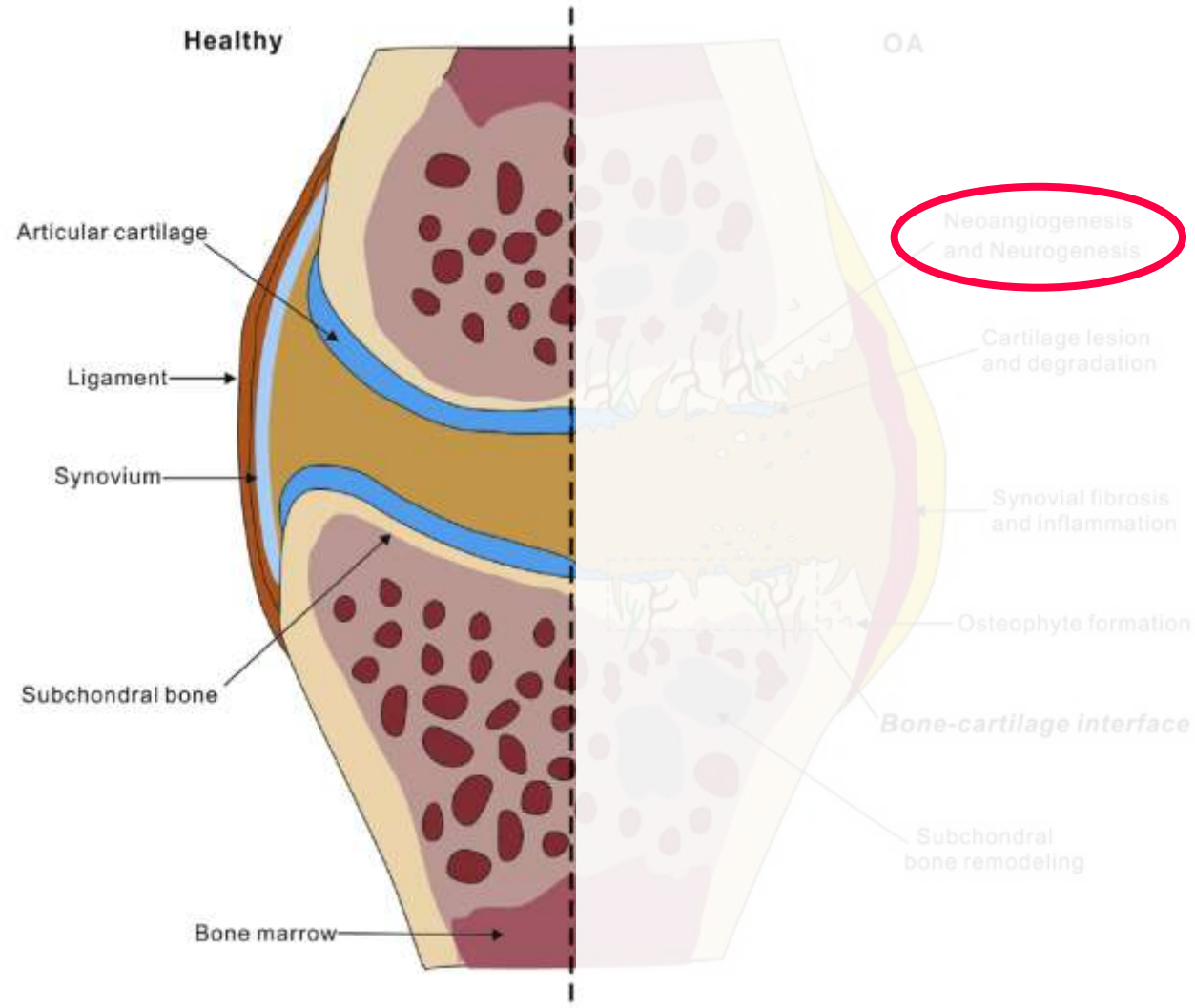
- Consulting
- Employment in industry
- Stockholder of a healthcare company
- Owner of a healthcare company
- Other(s)
  
- I do not have any potential conflict of interest

# Painful joints



# Osteoarthritis

Yuan et al. Osteoarthritis and Cartilage 2014



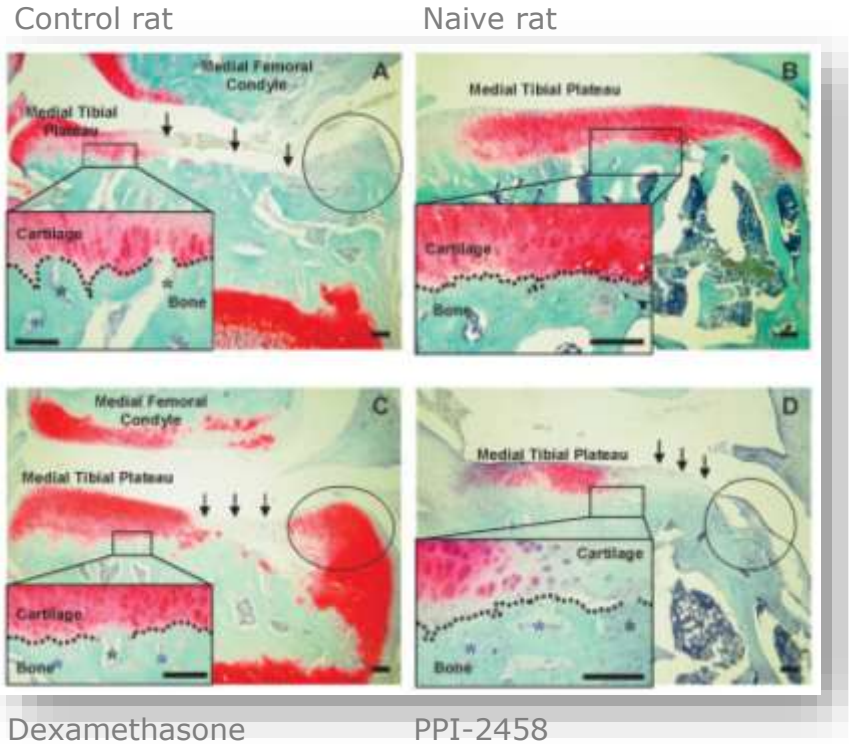
# Pathophysiology

Arthritis and Rheumatism 2011

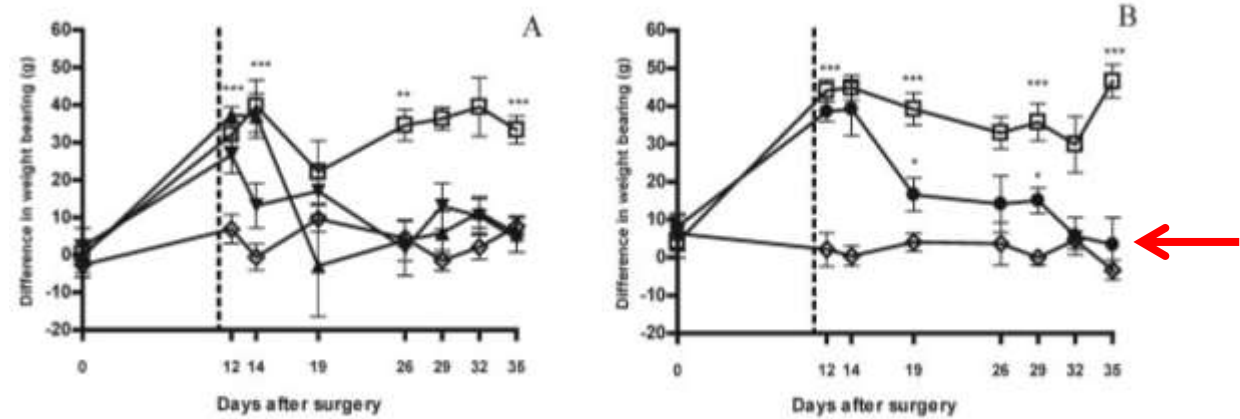


## Contributions of Angiogenesis to Inflammation, Joint Damage, and Pain in a Rat Model of Osteoarthritis

Sadaf Ashraf, Paul I. Mapp, and David A. Walsh



Pain behavior after meniscal transection



- ▼ Indomethacin
- ▲ Dexamethason
- Vehicle
- PPI-2458 (specific angiogenesis inhibitor)



# Pathophysiology

Normal status:

**Avascular** and **aneural** articular cartilage

In osteoarthritis:

- **Angiogenesis**
- **Neurogenesis** with new sympathetic and sensory nerves
- **Synovitis**

→ symptoms, destructions

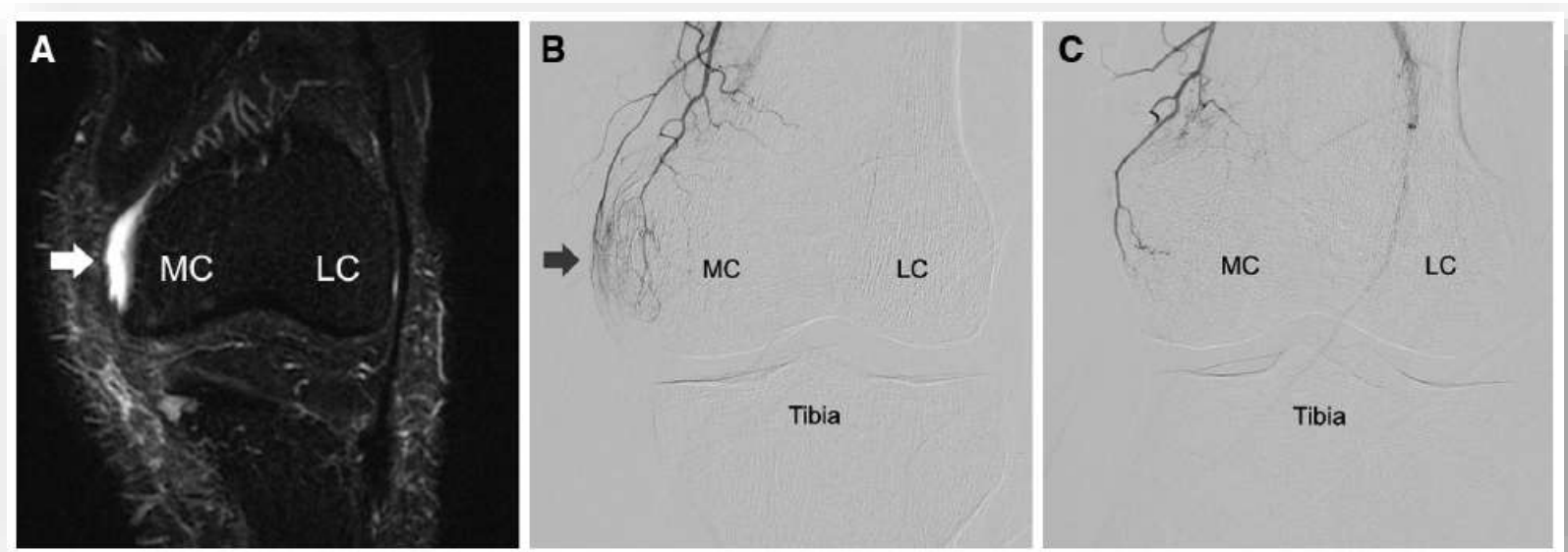
**Embolization** leading to ...  
... excitability of the redundant nerves ↓  
... vicious circle of inflammation ↓



# First publication

## Transcatheter Arterial Embolization as a Treatment for Medial Knee Pain in Patients with Mild to Moderate Osteoarthritis

Yuji Okuno · Amine Mohamed Korchi ·  
Takuma Shinjo · Shojiro Kato



Cardiovasc Intervent Radiol (2015) 38:336–343



# Results after TAPE of the Knee



## **Midterm Clinical Outcomes and MR Imaging Changes after Transcatheter Arterial Embolization as a Treatment for Mild to Moderate Radiographic Knee Osteoarthritis Resistant to Conservative Treatment**

Yuji Okuno, MD, PhD, Amine M. Korchi, MD, Takuma Shinjo, MD, Shojiro Kato, MD, PhD, and Takao Kaneko, MD, PhD

*J Vasc Interv Radiol 2017; 28:995–1002*

- 72 patients (95 knees)
- WOMAC Pain score:  $12.1 \pm 2.3$  (baseline),  $2.6 \pm 3.4$  (24 months)
- Clinical success rate 80% (24 months)



# Results after TAPE of the Knee



*J Vasc Interv Radiol 2017; 28:995-1002*

**Table 2. Details of Patients Who Used Other Conservative Treatments**

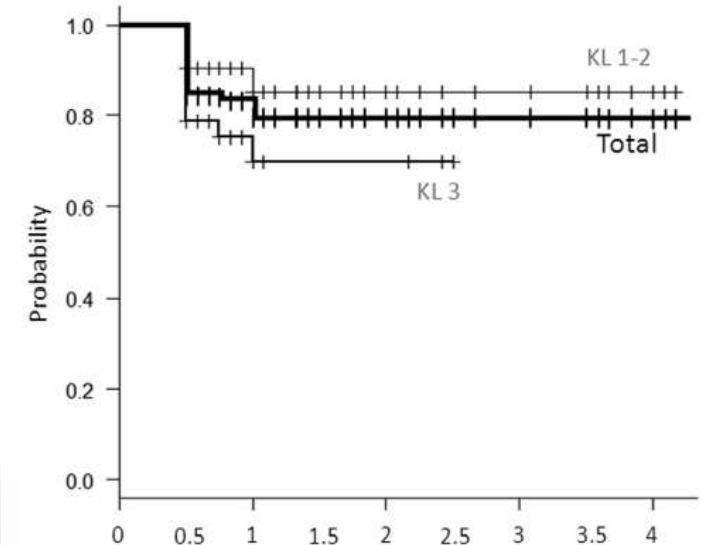
| Treatment           | Before Treatment (n = 72) | 1 mo (n = 72) | 6 mo (n = 72) | 12 mo (n = 52) | 24 mo (n = 30) |
|---------------------|---------------------------|---------------|---------------|----------------|----------------|
| <b>Oral NSAIDs</b>  |                           |               |               |                |                |
| Daily               | 28                        | 8             | 2             | 1              | 1              |
| As needed           | 11                        | 8             | 4             | 3              | 3              |
| <b>Oral opioids</b> |                           |               |               |                |                |
| Daily               | 20                        | 8             | 3             | 2              | 2              |
| As needed           | 2                         | 4             | 0             | 0              | 0              |
| <b>HA injection</b> |                           |               |               |                |                |
| Routinely           | 29                        | 0             | 0             |                |                |
| As needed           | 14                        | 11            | 5             |                |                |

HA = hyaluronic acid; NSAID = nonsteroidal drug.

**Table 3. Change in WORMS Scores**

| WORMS Score        | Baseline          | 2 y               | P Value      |
|--------------------|-------------------|-------------------|--------------|
| Cartilage          | 22.4 ± 9.9        | 22.5 ± 9.9        | .956         |
| Marrow abnormality | 1.89 ± 1.8        | 1.75 ± 1.9        | .603         |
| Bone cysts         | 0.34 ± 0.6        | 0.35 ± 0.6        | .771         |
| Bone attrition     | 1.58 ± 1.3        | 1.62 ± 1.4        | .992         |
| Osteophytes        | 12.6 ± 9.1        | 14.3 ± 10.2       | .422         |
| Menisci            | 1.62 ± 1.6        | 1.69 ± 1.6        | .856         |
| Ligament           | 0.07 ± 0.2        | 0.07 ± 0.2        | 1.000        |
| <b>Synovitis</b>   | <b>1.52 ± 0.8</b> | <b>0.72 ± 0.6</b> | <b>.0016</b> |
| Total              | 42.0 ± 20.1       | 43.1 ± 21.3       | .838         |

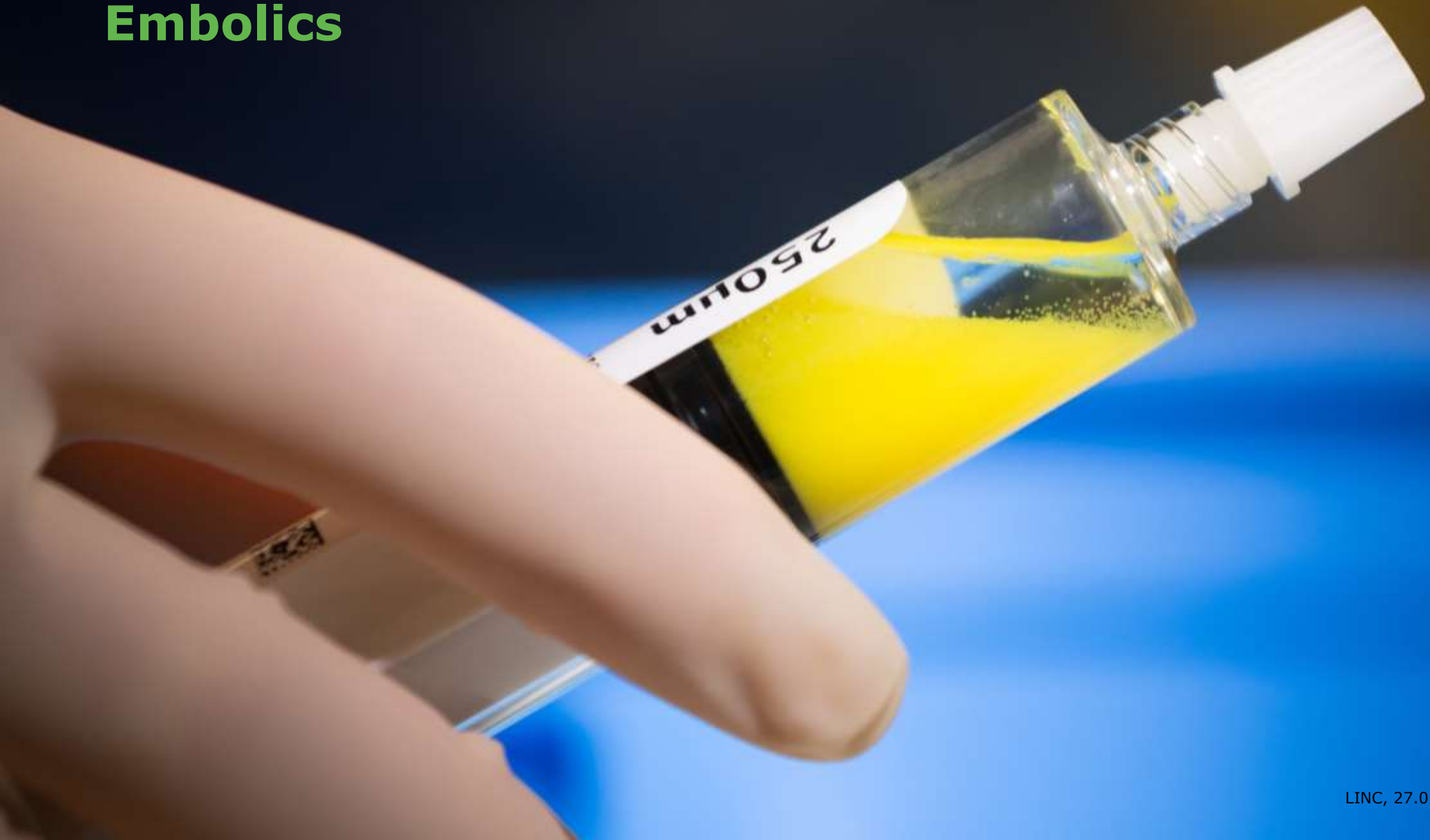WORMS = Whole-Organ Magnetic Resonance Imaging Scoring.



|                       |    | 0  | 0.5 | 1  | 1.5 | 2  | 2.5 | 3  | 3.5 | 4 |
|-----------------------|----|----|-----|----|-----|----|-----|----|-----|---|
| <b>Number at risk</b> |    |    |     |    |     |    |     |    |     |   |
| Total                 | 95 | 95 | 67  | 47 | 37  | 24 | 14  | 10 | 4   |   |
| KL 1-2                | 62 | 62 | 49  | 39 | 29  | 20 | 14  | 10 | 4   |   |
| KL 3                  | 33 | 33 | 18  | 8  | 8   | 4  | 0   | 0  | 0   |   |

**Figure 3.** Kaplan-Meier estimates of cumulative clinical success after transcatheter arterial embolization.

# Embolics





# Embolics

Imipenem (Zienam® 500 mg)

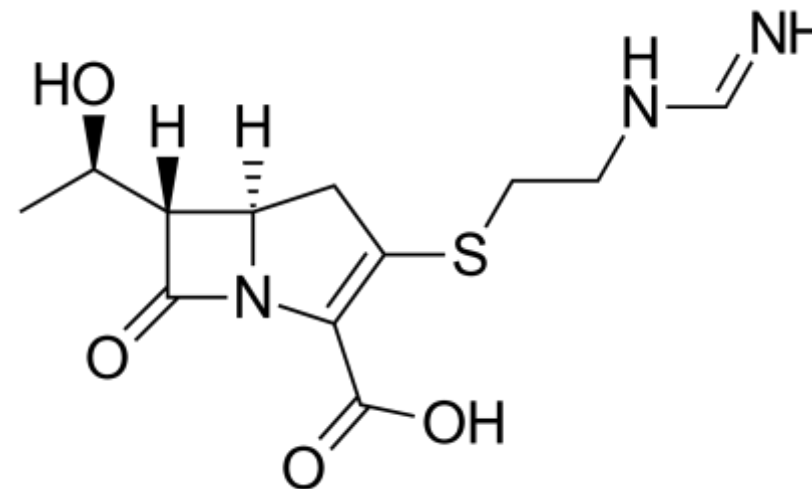
Beta-lactam-antibiotic

→ Inhibition of bacteria cell synthesis

White powder

→ Particle size of 10 – 70 µm

Transient embolization

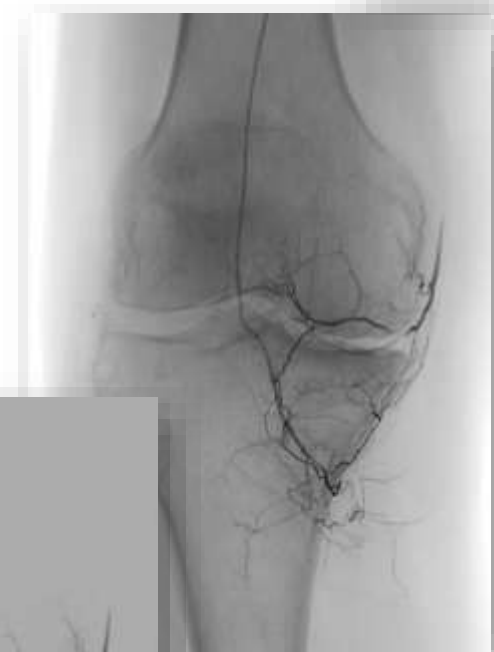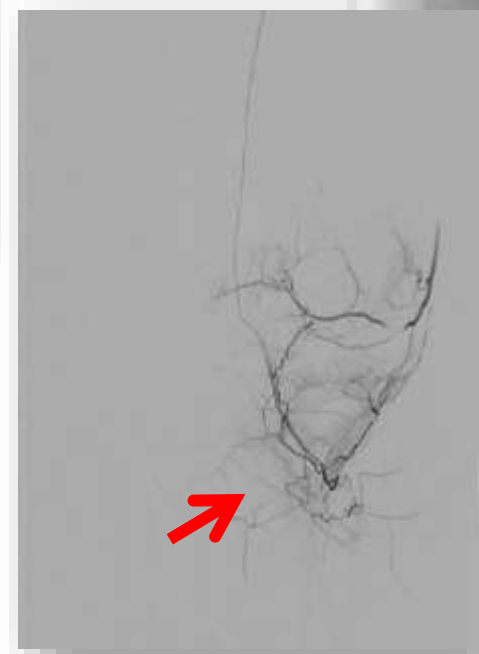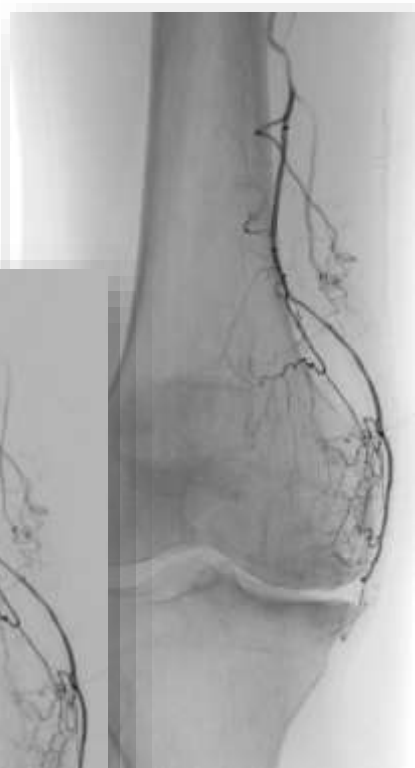
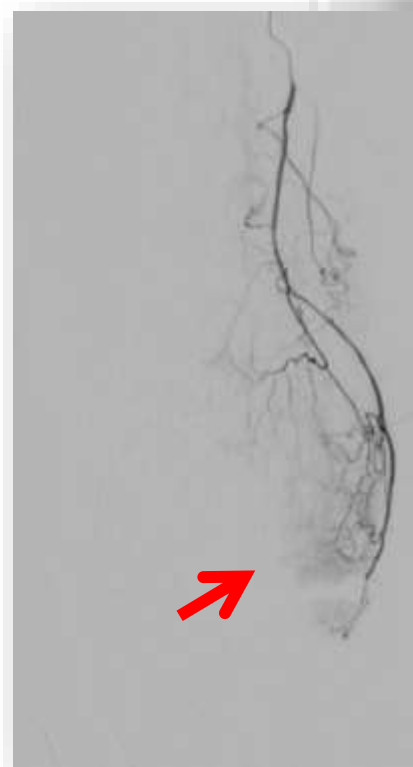


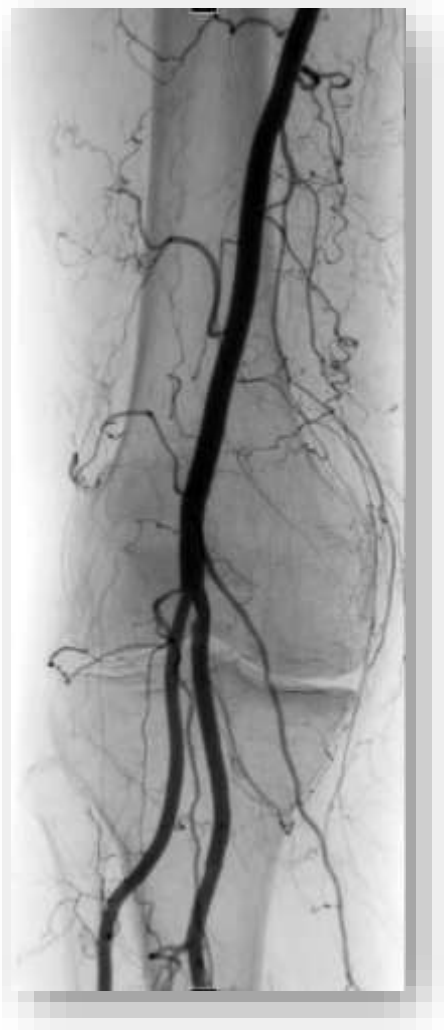

# Indications

- Chronic osteoarthritis
- „Frozen Shoulder“
- Tendinopathy
  
- Arthrofibrosis
- Rheumatoid arthritis

# Osteoarthritis





# Complications

- with Imipenem
  - skin reddening
  
- with particles
  - skin ulcer / necrosis
  - osteonecrosis
  - paresthesia



... thank you!

