

**Case 04 Leipzig 3:
male, 79 years**

BTK-CTO left, Re-occlusion with restpain

Operators: A. Schmidt, A. Fischer

Case 04 Leipzig 3: male, 79 years

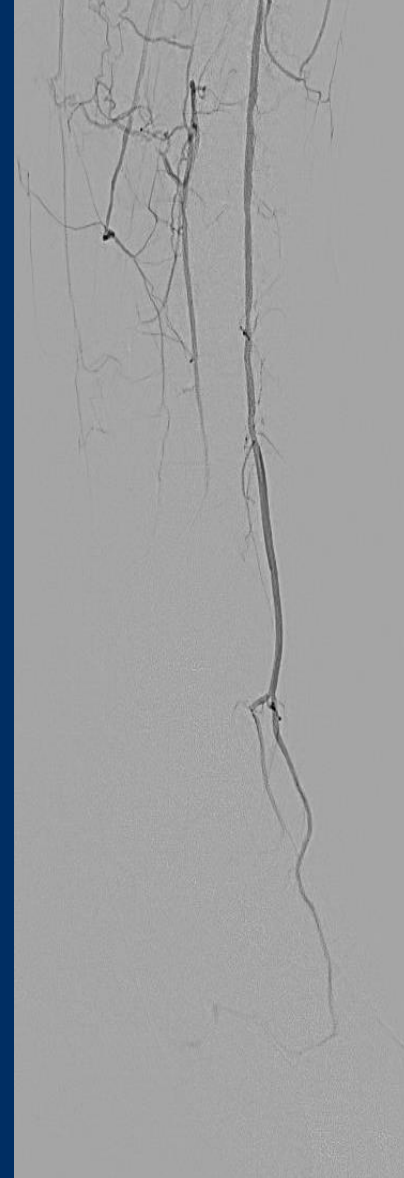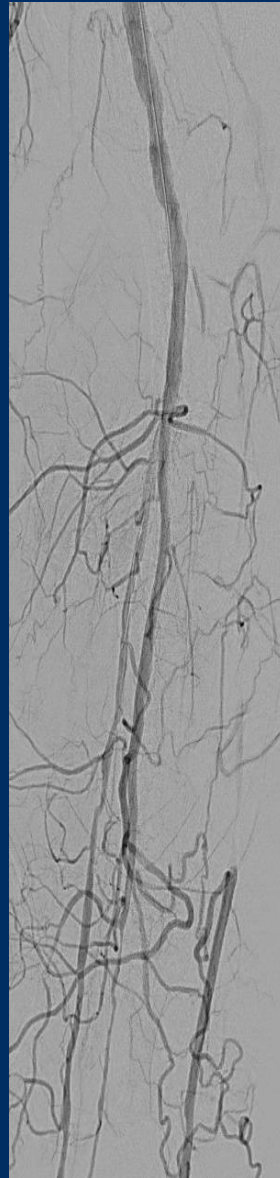
- **Clinical data:**

- Critical limb ischemia left, restpain at night
- ABI left 0.46, Rutherford class 4
- PTA / stenting femoropopliteal 2018 / 2020
- CAD, MI 1998, PTCA
- Stroke, CAS 2004
- EVAR 2017
- CKD (GFR 56ml/min)

Case 04 Leipzig 3: male, 79 years

- **Risk factors:**
 - Hypertension
 - Former smoker
 - Adipositas
 - HLP

Case 04 Leipzig 3: male, 79 years



Case 04 Leipzig 3: male, 79 years

- **Procedural Steps:**
 - Antegrade access left groin
 - Antegrade guidewire passage
 - In case of failure to pass from antegrade:
 - retrograde approach via distal ATA
 - PTA and stenting with DES (Xience-Prime)