

**Case 02 Münster 1:
female, 64 years (G-U)**

**Transradial stenting of iliac artery
stenoses**

Operators: A. Schwindt, E. Beropoulos

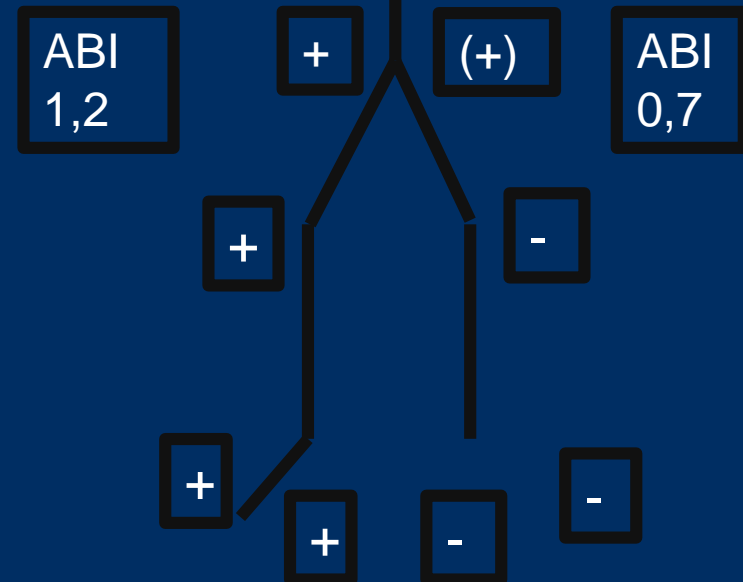
Case 02 Münster 1: female, 64 years (G-U)

- **Clinical data:**

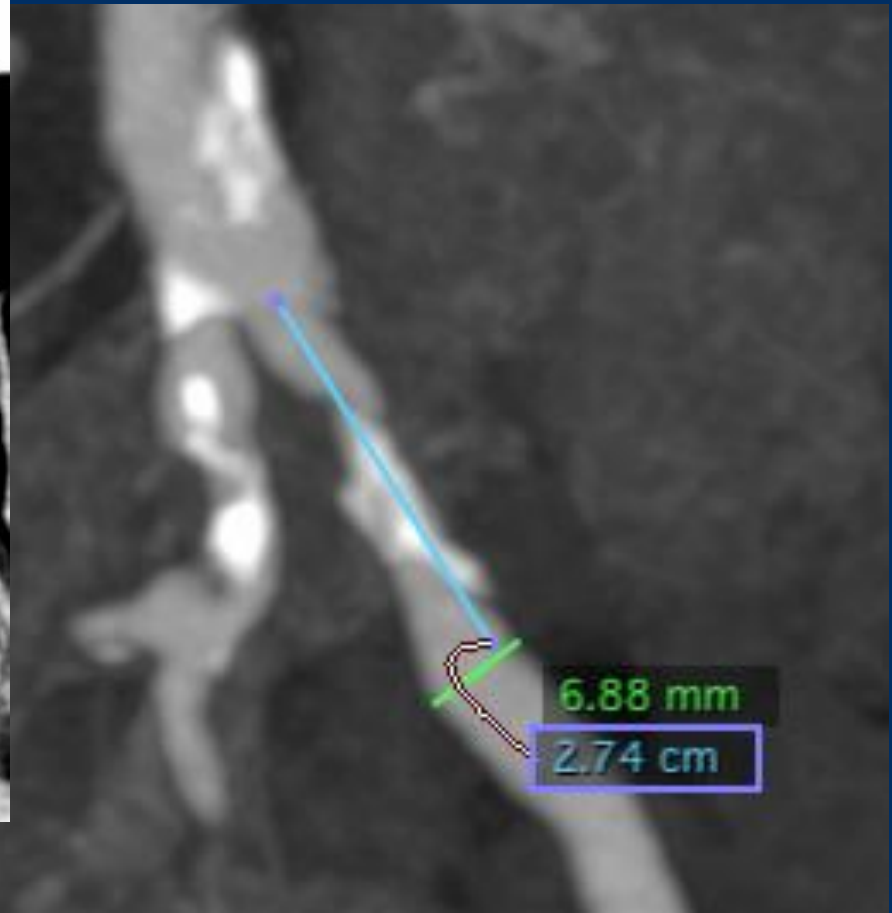
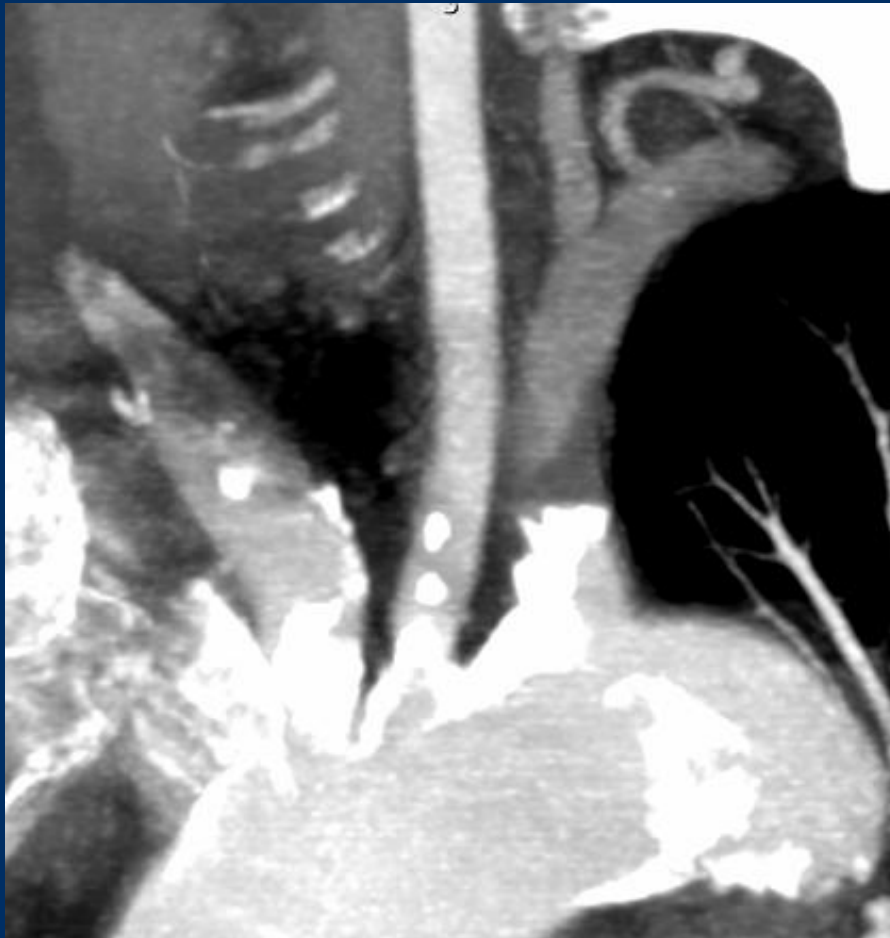- PAD Rutherford III with WD limited to 100 meters
- Weak pulses left arm, syst.BP right: 190 left:140
- CT-Angio: left subclavian artery occlusion , high grade EIA stenosis

- **Risk factors:**

- arterial hypertension



Case 02 Münster 1: female, 64 years (G-U)



Case 02 Münster 1: female, 64 years (G-U)

- **Procedural steps:**

- US guided access left radial artery (Micropuncture set Cook)
- Change to 6F 90cm Fortress sheath (Biotronik)
- Stent-PTA left subclavian artery 9x28 Dynetic (Biotronik)
- Canulation of left EIA stenosis with 0,35 wire (Terumo)
- Stent PTA with 7x28mm Dynetic CoCr Stent 170cm working length

