

**Case 01 Leipzig 1:
male, 61 years**

Complex iliac occlusion left

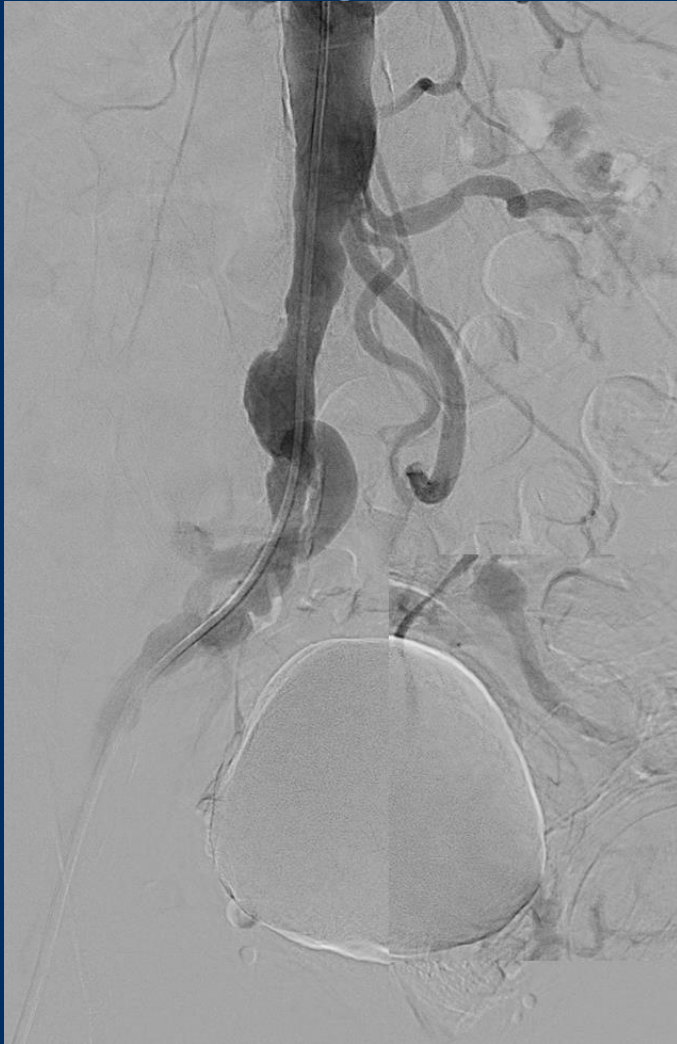Operators: A. Schmidt, A. Fischer

Case 01 Leipzig 1: male, 61 years

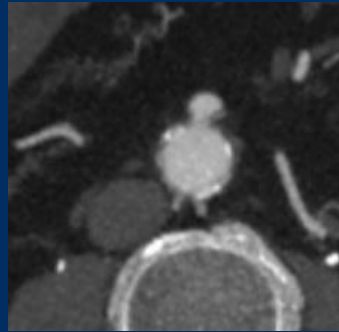
Clinical data:

- PAOD Rutherford 3, severe claudication left: buttock, thigh, calf, walking capacity 150m
- ABI left 0.75
- CAD, PTCA 12/2020
- Oropharyngeal carcinoma 2018
- Hypertension
- Smoker

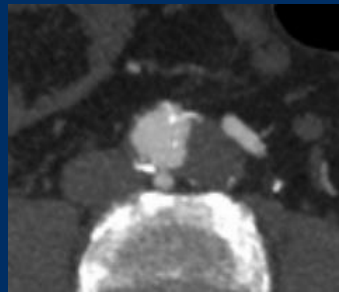
Case 01 Leipzig 1: male, 61 years



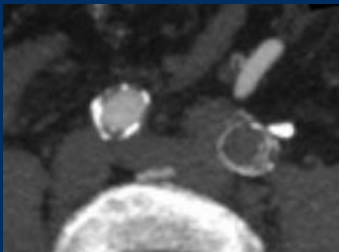
Angiography during PTCA



Aorta at the level of the
inferior mesenteric artery



Aortic bifurcation



Common iliac artery

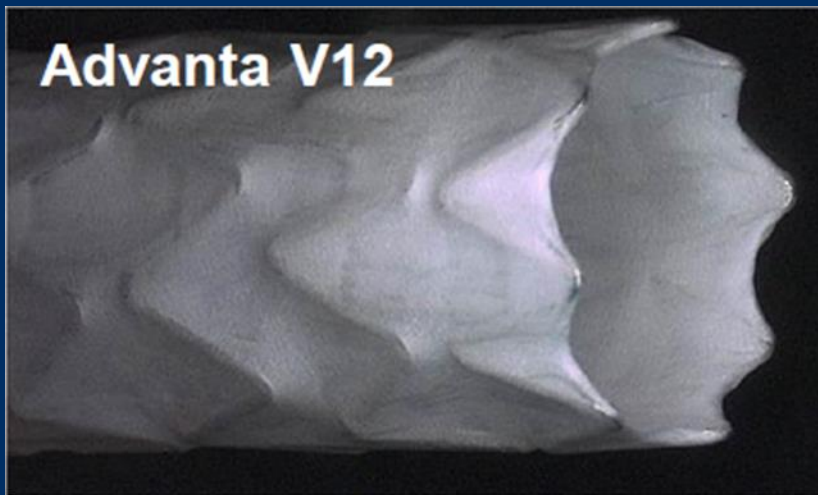
Case 01 Leipzig 1: male, 61 years

Procedural Steps:

- Left brachial and left groin access 7French
- Guidewire passage left CIA bidirectional
- PTA in Kissing-technique
- Implantation of covered Stents (Advanta V12)

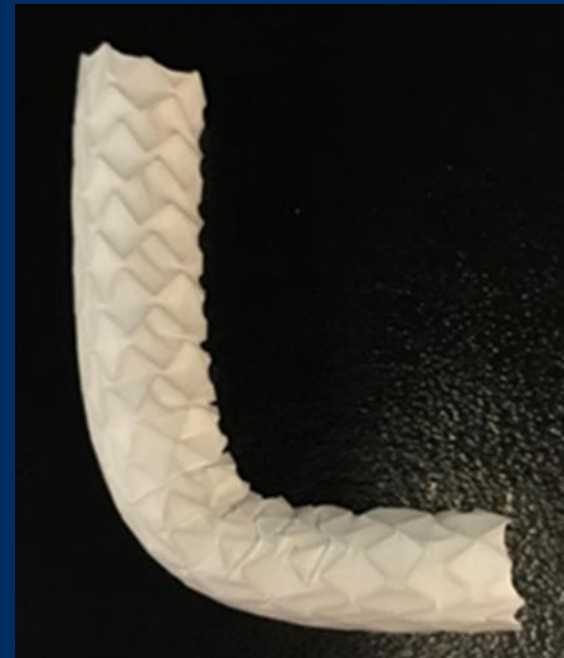Case 01 Leipzig 1: male, 61 years

Advanta V12 (Getinge)



Double layer, one-piece of PTFE wrapped around ends and cuff overlapped in center.

Diameter 5 – 10mm, maximally 7Fr. sheath



**Advanta V12 8 x 59 mm
at 90° bending**

Diameter 12mm, 29; 41; 61mm length maximally 9Fr. Sheath
Postdilatation to 16mm possible